

Successively bilateral cytomegalovirus retinitis in immunocompromised patient with Good's syndrome

Feng Hu^{1,2}, Yuan Du^{1,2}, Xiao-Yan Peng^{1,2}

¹Beijing Institute of Ophthalmology, Beijing 100005, China

²Beijing Tongren Eye Center, Beijing Tongren Hospital, Capital Medical University, Beijing 100730, China

Correspondence to: Xiao-Yan Peng. 17 Hougou Lane, Chongnei Street, Beijing 100730, China. Drpengxy2017@163.com

Received: 2017-07-02 Accepted: 2018-11-21

DOI:10.18240/ijo.2018.12.24

Citation: Hu F, Du Y, Peng XY. Successively bilateral cytomegalovirus retinitis in immunocompromised patient with Good's syndrome. *Int J Ophthalmol* 2018;11(12):2021-2023

Dear Editor,

I am Dr. Feng Hu, from the Department of Ophthalmology of Beijing Tongren Hospital, Beijing, China. I write to present a case report of cytomegalovirus retinitis (CMVR) in Good's syndrome (GS).

GS is an extremely rare primary immune-deficiency syndrome, which consists of simultaneous occurrence of hypogammaglobinemia and thymoma, and is characterized by both humoral and cellular immunodeficiency^[1]. CMVR is common in acquired immune deficiency syndrome (AIDS) patients but can also be observed in patients with other forms of immunocompromised status in the absence of human immunodeficiency virus (HIV) infection^[2]. The ocular cytomegalovirus infection was reported in form of vitritis, multiple or peripheral necrotizing retinitis^[2-3], retinal hemorrhage, occlusive vasculitis^[4] and optic neuritis in GS patients^[5]. Most reported cases of CMVR in GS were unilateral except one^[2], herein, we report a case of successively bilateral CMVR in GS patient.

A 55-year-old man visited a general hospital for painful oral ulcer, genital ulcer and erythra all over the body, especially severe on stomach, back, upper and lower limbs in August. He was given oral prednisolone (30 mg daily) and reduced 5 mg every four days. The erythra vanished gradually, but the dental and genital ulcer did not relieve. He noticed progressive vision loss in the right eye for one month and visited our clinics in November. Besides, he complained about consistent fever for recent two weeks. The patient had the history of thymoma, recurrent dental ulcer for three years, more than three times per year. He denied the history of hypertension, diabetes mellitus,

arthritis, tuberculosis, hepatitis, syphilis, shingles, fever blisters, operation and trauma.

His initial visual acuity was hand move and 6/9 in left eye. The intraocular pressure was 15 mm Hg in the right eye and 17 mm Hg in the left eye. Relative afferent pupillary defect (RAPD) was positive for the right eye and negative for left eye. Slit-lamp bio-microscopy on the right eye revealed diffusely fine grey keratic precipitates, aqueous cells and flare, while the left anterior chamber was unremarkable. Dilated right fundus showed severe hemorrhage and exudations near optic disk, and the left fundus was unremarkable (Figure 1A, 1B). Fluorescence angiography (FA) and indocyanine green angiography (ICGA) revealed hypo-fluorescence caused by hemorrhage blockage and several micro-aneurysms around optic disk (Figure 2). The initial diagnosis was Behcet disease (BD) with supports of painful oral ulcers, genital ulcer and eye lesions. However, the oral ulcers in this patient were not the typical aphthous ulcers (well-defined borders with white yellow necrotic center, and surrounded by erythema), but appeared to be thrush-like with extensive thick white discharge. Considering the consistent fever and unilateral eye lesion, the potential fungal, bacterial and virus infection needed to be included in differential diagnosis.

The brain MRI showed abnormal enhanced signal on anterior intra-orbital part of right optic nerve. The chest CT revealed a mediastinal mass of 7.6×4.5×6.1 cm³ with clear border appeared as soft tissue density in the region of thymus. In blood routine test, the white cell count was 3.8×10⁹/L (reference range, 4-10×10⁹/L), mononuclear cell was 15.2% (reference range, 3.4%-14%) and other blood count and percentage were among normal range. The B lymphocyte was 0, total T lymphocyte (CD3+) was 82.4% (reference range, 60.5%-75.4%), T helper lymphocyte (Th CD3+CD4+) was 26.5% (reference range, 32.8%-52.8%), T suppressive lymphocyte (Ts CD3+CD8+) was 50% (reference range, 19.7%-38.9%) and Th/Ts was 0.53 (reference range, 1.0-2.16). The C-reactive protein was 53 mg/L (reference range, <8). The IgG was 1.79 g/L (reference range, 7.23-16.85), IgA was 0.11 g/L (reference range, 0.69-3.82), IgM was 0.06 g/L (reference range, 0.63-2.77). The culture of throat swab was 2+ positive for candida albicans. Blood culture for aerobic and anaerobic bacterium was negative. In blood TORCH test, the cytomegalovirus-IgG and herpetic simplex virus-IgG were positive, and others were

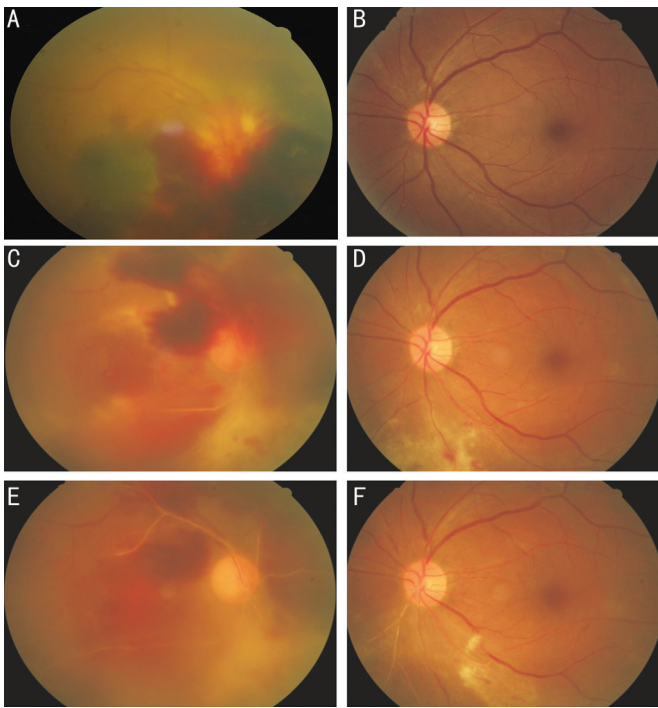


Figure 1 Fundus photograph of cytomegalovirus retinitis patient with Good's syndrome A, B: Fundus photograph of right eye taken at first visit to ophthalmic clinics, showing severe hemorrhage and exudations near optic disk, and left fundus was unremarkable; C, D: Fundus photograph of right eye taken after twice intravitreal injection of ganciclovir and thymectomy, showing aggravation with wider hemorrhage, unclear fundus and whitening retinal vessels, and left fundus showed exudations and focal hemorrhage inferior to optic disk, the optic disk and macular were not involved; E, F: Fundus photograph of right eye taken after one week of intravenous ganciclovir, showing fundus became clear and hemorrhage was partially absorbed, and left fundus showed white sheath of inferior nasal arteries.

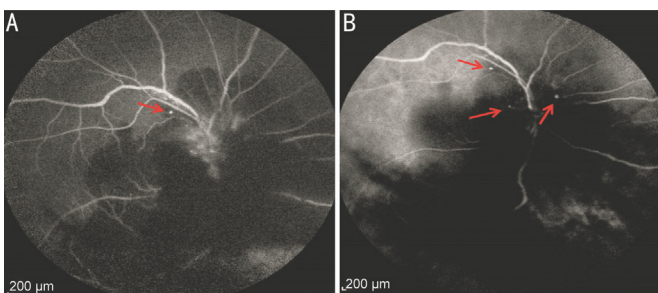


Figure 2 Late phase of FA (A) and ICGA (B) in right eye of CMVR, showing hypo-fluorescence around optic disk and micro-aneurysms (arrows) around optic disk.

negative. The patient subsequently underwent tests including hepatic B and C, treponema pallidum specific antibody, HIV, interferon gamma release assay (T-SPOT), rheumatoid factor, antinuclear antibody, anti-neutrophil cytoplasmic antibodies, erythrocyte sedimentation rate and urine routine, all of which were negative. The result of purified protein derivative (PPD) was negative.

The patient was diagnosed GS with characteristics of thymoma and hypogammaglobulinemia. Considering the low Th/Ts (CD4+/CD8+) rate and oral fungal infection, the patient was diagnosed as immunocompromised status. The anterior chamber paracentesis and further aqueous humor viral detection was undertaken. The PCR results of aqueous humor were positive for cytomegalovirus and negative for herpes simplex virus (HSV-1 and HSV-2), varicella zoster virus (VZV) and Epstein-Barr virus (EBV). Therefore, the patient was diagnosed as CMVR and given intravitreal injection of ganciclovir (2 mg in 0.1 mL).

After twice intravitreal injection of ganciclovir, the visual acuity of right eye improved to figure count, and the patient went through thymectomy. One month later, he back to our clinics to check again, the lesions aggravated with wider hemorrhage, unclear fundus and whitening retinal vessels. In the meanwhile, although left eye was asymptomatic, the fundus showed exudations and focal hemorrhage inferior to optic disk, the optic disk and macular were not involved (Figure 1C, 1D). He was given intravenous ganciclovir (5 mg/kg every 12h) for one week. One month later the right fundus became clear and hemorrhage was partially absorbed, and the left fundus showed white sheath of inferior nasal arteries (Figure 1E, 1F). Three months later, his right visual acuity remained at “figure counting” ahead of right eye 20 cm, and the left visual acuity remained at 6/9.

CMVR is known to be associated with immunocompromised status. Clinically, HIV-associated CMVR includes classic features of necrotizing retinitis with irregular sheathing of adjacent vessels and variable degrees of hemorrhage (sometimes referred to as “pizza pie retinopathy” or “cottage cheese with ketchup”), and which is sometimes coupled with a frost branch angiitis appearance without vascular occlusion and often associated with mild vitreous or anterior chamber inflammation^[6-8].

In a previous comprehensive review of CMVR in the absence of HIV infection, the most common factors for immunosuppression included age over 60y, an underlying malignancy, a systemic autoimmune disorder, bone marrow or organ transplantation, prior intraocular or periorbital corticosteroid administration and diabetes mellitus^[2]. Several studies suggested that HIV-negative CMVR was more often associated with moderate to severe vitreous inflammation, cystic macular edema and occlusive vasculitis, which showed similarity to acute retinal necrosis^[9-10].

GS, first described by Robert Good in 1954, is an extremely rare primary immune-deficiency syndrome, which consists of simultaneous occurrence of hypogammaglobulinemia and thymoma, and is characterized by both humoral and cellular immunodeficiency. Opportunistic infections, such as mucocutaneous candidiasis, herpes zoster, Pneumocystis

carinii pneumonia, cytomegalovirus disease, and recurrent herpes simplex virus infections have been associated with GS^[1,4,11-14]. CMVR rarely accompanies GS, only nine cases have been reported in the previous literature^[4]. The CMVR in patients with GS have been reported developing vitritis, multiple or peripheral necrotizing retinitis^[2-3], retinal hemorrhage, occlusive vasculitis^[4], optic neuritis^[5]. In the present case, the patient had unilateral severe vitritis, necrotizing retinitis, hemorrhage around optic disk and optic neuritis. The previously healthy eye gradually developed retinitis in the follow-up, so we observed early manifestation of CMVR which was followed by adjacent arterial sheathing one month later. The CMVR in GS have been reported having poor prognosis including 55% with final visual acuity between 20/40 and 20/200, and 45% worsen than 20/200^[2]. Only one case of bilateral CMVR in GS has been reported, but with poor prognosis of counting fingers at 30 cm in one eye and no light perception in the other eye^[5]. In the present case, the intravenous ganciclovir was undertaken immediately after the previously healthy eye was diagnosed CMVR, before the patient noticed any visual acuity decrease. Fortunately, the lesion gradually vanished and visual acuity was not influenced. The prompt intravenous antiviral therapy was possibly associated with good prognosis in this case.

In conclusion, although the reported cases of CMVR and GS are limited, this case emphasized the importance of awareness of GS. CT, T/B lymphocyte and serum immunoglobulin level in patients with CMVR in the absence of HIV infection should be considered for underlying primary immunocompromised disease.

ACKNOWLEDGEMENTS

Foundation: Supported by the Capital Health Research and Development of Special (No.SF-2018-2-1081).

Conflicts of Interest: Hu F, None; Du Y, None; Peng XY, None.

REFERENCES

- 1 Kelesidis T, Yang O. Good's syndrome remains a mystery after 55 years: a systematic review of the scientific evidence. *Clin Immunol* 2010;135(3):347-363.
- 2 Downes KM, Tarasewicz D, Weisberg LJ, Cunningham ET Jr. Good

syndrome and other causes of cytomegalovirus retinitis in HIV-negative patients-case report and comprehensive review of the literature. *J Ophthalmic Inflamm Infect* 2016;6(1):3.

3 Assi AC, Lightman S. Clinicopathologic reports, case reports, and small case series: cytomegalovirus retinitis in patients with Good syndrome. *Arch Ophthalmol* 2002;120(4):510-512.

4 Lee SW, Lee YW, Bae JH. Cytomegalovirus retinitis as the first manifestation of good syndrome. *Ocul Immunol Inflamm* 2018;26(1):122-124.

5 Park DH, Kim SY, Shin JP. Bilateral cytomegalovirus retinitis with unilateral optic neuritis in Good syndrome. *Jpn J Ophthalmol* 2010;54(3):246-248.

6 Jabs DA. Cytomegalovirus retinitis and the acquired immunodeficiency syndrome: bench to bedside: LXVII edward jackson memorial lecture. *Am J Ophthalmol* 2011;151(2):198-216.e1.

7 Jabs DA, van Natta ML, Holbrook JT, Kempen JH, Meinert CL, Davis MD. Longitudinal study of the ocular complications of AIDS 1. ocular diagnoses at enrollment. *Ophthalmology* 2007;114(4):780-786.e3.

8 Jabs DA, Van Natta ML, Holbrook JT, Kempen JH, Meinert CL, Davis MD, Studies of the Ocular Complications of AIDS Research Group. Longitudinal study of the ocular complications of AIDS: 2. Ocular examination results at enrollment. *Ophthalmology* 2007;114(4):787-793.

9 Maguire AM, Nichols CW, Crooks GW. Visual loss in cytomegalovirus retinitis caused by cystoid macular edema in patients without the acquired immune deficiency syndrome. *Ophthalmology* 1996;103(4):601-605.

10 Schneider EW, Elnor SG, van Kuijk FJ, Goldberg N, Lieberman RM. Chronic retinal necrosis: cytomegalovirus necrotizing retinitis associated with panretinal vasculopathy in non-HIV patients. *Retina* 2013;33(9):1791-1799.

11 Inomata T, Honda M, Murakami A. Atypical VZV retinitis in a patient with good syndrome. *Ocul Immunol Inflamm* 2018;26(2):194-198.

12 Akinosoglou K, Melachrinou M, Siagris D, Koletsis E, Marangos M, Gogos CA, Solomou EE. Good's syndrome and pure white cell aplasia complicated by cryptococcus infection: a case report and review of the literature. *J Clin Immunol* 2014;34(3):283-288.

13 Wan CK, Teoh SC. Autoimmune retinopathy in benign thymoma after good syndrome-associated cytomegalovirus retinitis. *Ocul Immunol Inflamm* 2013;21(1):79-81.

14 Mateo-Montoya A, Stanescu D, Wolff B, Sahel JA, Bonnel S. Cytomegalovirus retinitis associated with Good's syndrome. *Eur J Ophthalmol* 2010;20(2):479-480.