

Sutureless large-incision manual cataract extraction using the kongsap technique: outcome of a prospective study

Pipat Kongsap

Department of Ophthalmology, Prapokklao Hospital, Chanthaburi 22000, Thailand

Correspondence to: Pipat Kongsap, MD. Department of Ophthalmology, Prapokklao Hospital, Chanthaburi 22000, Thailand. pkongsap@yahoo.com, pkongsap@gmail.com

Received:2010-07-16 Accepted:2010-08-28

Abstract

- **AIM:** To report the short- and medium-term outcomes of sutureless large-incision manual cataract extraction using the Kongsap (SLIMCE-K) technique.
- **METHODS:** This prospective study included 73 eyes of 73 patients who underwent cataract surgery performed by using the SLIMCE-K technique. The postoperative visual acuity, intraoperative and postoperative complications, and endothelial cell loss were evaluated. A follow-up visit, at least 6 months after the surgery, was included in the study.
- **RESULTS:** All patients had improved visual acuity after surgery. Uncorrected visual acuity (UCVA) was 6/18 or better in 55 eyes (75.3%) at 1 week postoperatively and in 64 eyes (87.6%) at 6 weeks postoperatively ($P=0.09$). The best corrected visual acuity (BCVA) was 6/18 or better in 67 eyes (91.8%) at 1 week postoperatively and in 70 eyes (95.9%) at 6 weeks postoperatively. The results remained stable at 3 months and 6 months postoperatively. No significant intraoperative complications were encountered. The endothelial cell loss was 4.8% at the 3-month follow-up examination.
- **CONCLUSION:** When performed by an experienced surgeon, SLIMCE-K is a safe and effective procedure that can be performed independent of phacoemulsification machines. It can be used in any nuclear grading of cataract hardness that is common in developing countries.
- **KEYWORDS:** manual small-incision cataract surgery; large-incision cataract surgery; complications; endothelial cell density
DOI:10.3980/j.issn.2222-3959.2010.03.14

Kongsap P. Sutureless large-incision manual cataract extraction using the kongsap technique: outcome of a prospective study. *Int J Ophthalmol* 2010;3(3):241-244

INTRODUCTION

Ophthalmologists working within developing countries are currently exploring possible alternatives to phacoemulsification in order to obtain the advantages of a self-sealing sutureless incision at a considerably lower cost. Manual small-incision cataract surgery has now been used to perform ECCE without phacoemulsification. The techniques for this surgery include the Ruit technique, Blumenthal technique, Quarters extraction technique, Nylon Loop technique, Prechop Manual Phacofragmentation, phaco-trisection, manual phacocracking, manual multiphacofragmentation, and Fishhook technique^[1-10].

The Kongsap technique is a manual small-incision cataract surgery in which the lens nucleus is divided into 3 fragments prior to manual removal through a relatively small clear corneal incision, using inexpensive instrumentation, namely, a nuclear supporter and a nuclear cutter^[11]. The incision is small, yet large enough to allow implantation of the foldable intraocular lens. The wound is closed without any stitches. A phacoemulsification machine is not needed. Basically, this technique is good for soft to medium-hard cataracts. It is difficult to divide the hard nuclear cataract that is more common in developing countries. The author of this paper modified the surgical technique by dividing the nucleus into 2 fragments (like the Kongsap technique) and then removing each fragment through a large temporal scleral tunnel incision, like the large incision in sutureless large-incision manual cataract extraction (SLIMCE). The purpose of this study was to evaluate the visual outcome and complications of this modified sutureless surgical technique.

MATERIALS AND METHODS

Materials This prospective study was made up of 73 consecutive patients who underwent sutureless large-incision manual cataract extraction using the Kongsap (SLIMCE-K) technique performed by a single experienced surgeon (P.K.) between October 2008 and November 2009, and who completed at least a 6-month follow-up schedule. All consenting patients with an age-related cataract who were admitted for surgery were potentially eligible. Patients with ocular pathology or previous ocular surgery were excluded.

Outcomes of SLIMCE-K technique

Methods Patient data included sex, age, a detailed preoperative ocular examination, visual acuity, and intraoperative and postoperative complications. The specular microscopy images, obtained by selecting 100 adjacent cells for calculation before surgery and 3 months after surgery, were used to determine the surgically-induced endothelial cell loss. The main outcome measures were uncorrected visual acuity, best-corrected visual acuity, and intraoperative and postoperative complications. The secondary outcome measure was endothelial cell density.

Follow-up Patients were examined at 1 day, 1 week, 6 weeks, 3 months, 6 months, and 12 months after surgery. Visual acuities were analyzed according to the WHO definitions of good (6/18 or better), borderline (less than 6/18-6/60), and poor (less than 6/60) outcomes.

Surgical Technique Retrobulbar anesthesia of 2% lidocaine was administered. A paracentesis was made at the 6 o'clock position in the right eye with a 15-degree stab knife. A 6-6.5mm continuous curvilinear capsulorhexis (CCC) was performed with a 27-gauge bent needle while the anterior chamber was filled with a balanced salt solution. A cystotome was connected to an insulin syringe and a bottle of Balanced Salt Solution and then introduced through the 6 o'clock side port. A 6.0-7.0mm scleral tunnel incision, 2.0mm from the limbus, was made on the temporal side using a crescent knife (Figure 1). Hydrodissection, subsequently followed by hydrodelineation, was performed. The anterior cortical debris was removed as much as possible in order to manipulate the hard core nucleus easily. Ophthalmic viscosurgical devices (ODVs) were then injected into the anterior chamber. The nucleus was dislocated out of the bag into the anterior chamber using a spatula and a Sinsky hook. The nuclear supporter was passed under the nucleus and the nuclear cutter was placed over the nucleus. The nucleus was slightly manipulated and then divided into 2 fragments by gently pushing the nuclear supporter and the nuclear cutter against each other. ODVs were then again injected below and above the nucleus. The nuclear supporter was then passed under the first fragment while the nuclear cutter was placed over it and the nucleus was pulled out. The second fragment was also extracted using the same technique. In some cases involving a soft nucleus, the entire nucleus can be extracted through the scleral tunnel incision without causing any nuclear fragmentation. The epinucleus and lens cortex were flushed out by gentle pressure on the sclera posterior to the incision. The residual cortex was irrigated with a Simcoe canula. A polymethylmethacrylate intraocular lens was implanted into the capsular bag. The wound was then closed with the conjunctiva, without a suture.

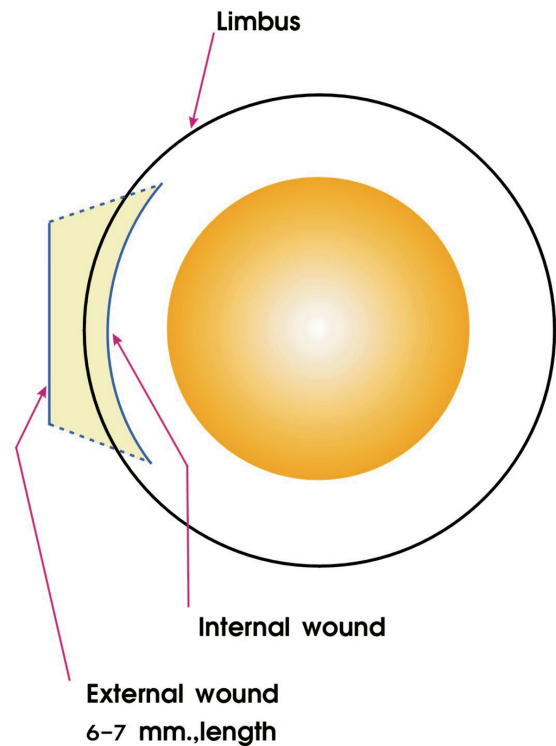


Figure 1 Scleral tunnel incision

Statistical Analysis Data were analyzed with SPSS 10.0 software. Chi-square tests were performed to compare visual acuity between 1 week and 6 weeks after surgery. The Student's *t*-test was used to compare the endothelial cell density; $P < 0.05$ was used as threshold for statistical significance.

RESULTS

SLIMCE-K was successfully performed in 73 eyes of 73 patients (28 men and 45 women) whose ages ranged from 48 to 87 years (mean age, 71.07 years). The mean follow-up was 6.38 months (range, 6 to 12 months). Sutureless wounds were achieved in all but 1 patient.

The distribution of preoperative uncorrected visual acuity (UCVA) was as follows: less than 6/60 in 38 patients (52.0%), 6/60 to 6/36 in 21 patients (28.8%), and at least 6/24 in 14 patients (19.2%). Seventeen patients (23.29%) had soft nuclear cataracts, 36 patients (49.31%) had intermediate nuclear-cortical cataracts, and 20 patients (27.40%) had dense hard cataracts.

All of the patients had improved visual acuity following surgery. The uncorrected visual acuity (UCVA), shown in Table 1, was 6/18 or better in 55 eyes (75.3%) at 1 week postoperatively and in 64 eyes (87.6%) at 6 weeks ($P=0.09$). At 3 months postoperatively, 89.0% had an UCVA of 6/18 or better without correction, which is not significantly different from the proportion achieving 6/18 unaided at 6 weeks ($P=1.00$).

The best corrected visual acuity (BCVA) was 6/18 or better

Table 1 Postoperative uncorrected visual acuity n(%)

Vision	Follow-up visits			
	1 week	6 weeks	3 months	6 months
6/6-6/9 (good)	50 (68.5)	55 (75.3)	57 (78.1)	56 (76.7)
6/12-6/18 (good)	5 (6.8)	9 (12.3)	8 (10.9)	9 (12.3)
6/24-6/60 (borderline)	17 (23.3)	8 (11.0)	7 (9.6)	7 (9.6)
<6/60 (poor)	1 (1.4)	1 (1.4)	1 (1.4)	1 (1.4)

Table 2 Postoperative best corrected visual acuity n(%)

Vision	Follow-up visits			
	1 week	6 weeks	3 months	6 months
6/6-6/9 (good)	66 (90.4)	69 (94.5)	69 (94.5)	68 (93.2)
6/12-6/18 (good)	1 (1.4)	1 (1.4)	1 (1.4)	2 (2.7)
6/24-6/60 (borderline)	5 (6.8)	2 (2.7)	2 (2.7)	2 (2.7)
<6/60 (poor)	1 (1.4)	1 (1.4)	1 (1.4)	1 (1.4)

in 67 eyes (91.8%) at 1 week and in 70 eyes (95.9%) at 6 weeks postoperatively (Table 2). The results remained stable at 3 months and 6 months postoperatively. One patient with a hard cataract had a postoperative visual acuity of 5/60. A 6-week fundus examination revealed a stage III macular hole.

Preoperatively, the mean endothelial cell density was 2434 ± 147 cell/mm² and 3 months after surgery the mean endothelial cell density was 2317 ± 174 cell/mm². There was a 4.8% loss of endothelial cells after surgery, which was statistically significant ($P=0.005$).

The most common intraoperative complication was iris prolapse (2 eyes, 2.74%). Other intraoperative complications were transient intracameral bleeding (1 eye, 1.37%) and minimal descemet membrane stripping (1 eye, 1.37%). Posterior capsule rupture or zonular dialysis was not seen in any of the 73 patients. The most significant postoperative complication was transient corneal edema, located at the corneal wound, which developed in 2 eyes (2.74%). Wound leakage was not observed in any of the cases. Posterior capsule opacity occurred in 1 eye, but a YAG capsulotomy was not required. No other significant complications, such as endophthalmitis or corneal decompensation, occurred in any of the eyes.

DISCUSSION

The aim of all manual small-incision cataract surgery is to reduce the size of any cataractous lens intraocularly, such that it can be extracted through a relatively small incision. With the Kongsap technique [11], the lens nucleus is divided into 3 fragments prior to manual removal through a clear corneal incision, using a nuclear supporter and a nuclear cutter. The foldable intraocular lens is implanted and the wound is closed without a suture. This technique provides excellent visual results and the endothelial cell loss is equivalent to that of phacoemulsification [12]. The procedure works well for soft to medium-hard cataracts, but less so

with the hard nuclear cataract, which is more common in developing countries, as the hard nuclear cataract is difficult to divide. With SLIMCE, which is described by Lam DS [13], the entire nucleus is extracted through a large scleral tunnel incision. With an incision of 8 mm, it is sometimes difficult to extract the entire nucleus of a large and hard cataract, and it is possible to induce more astigmatism.

The present study (SLIMCE-K) describes a modified manual cataract extraction technique, combining SLIMCE with the Kongsap technique. With this technique, the nucleus is divided into 2 fragments using a nuclear supporter and a nuclear cutter, and then removed through the 6-7mm scleral tunnel incision. The technique can be used in all nuclear gradings of cataract hardness, for both soft and hard cataracts.

Good visual outcomes were achieved for most of the cataract patients operated with the SLIMCE-K technique. A BCVA of 6/18 or better was achieved in 67 eyes (91.8%) at 1 week postoperatively, and this result increased to 70 eyes (95.9%) at 6 weeks.

The safety of the operation was reflected by the absence of significant intraoperative complications and a low rate (4.8%) of endothelial cell loss, which compared favorably with the rates reported for phacoemulsification [12,14], and manual SICS [3-5,7,11,14,15]. An endothelial cell loss rate of 4.8% obtained with SLIMCE-K is slightly higher than the rate obtained with original SLIMCE (3.9%), but lower than the rate obtained with original Kongsap technique (7.1%) [11].

Iris prolapse (2.74%), the most frequent intraoperative complication, occurred during the removal of the nucleus. It occurred because of early perforation into the anterior chamber of the wound.

The most significant postoperative complication to occur was transient corneal edema, which developed in 2 eyes (2.74%). The incidence of transient postoperative corneal edema is a bit higher than that found in patients who underwent original SLIMCE (2%), but lower than that found in patients who underwent the Kongsap technique (7.37%) and other Manual SICS [3-9].

As this technique is performed mainly in the anterior chamber, corneal endothelial damage may occur during the nuclear fragmentation and the nuclear removal through the clear corneal incision. The use of ODVs and progression in the learning curve can lower the incidence of endothelial-related complications. Patient selection is also important for surgical success. Patients with soft to medium-hard cataracts (nuclear grading I-III) [16], which allow for easier nuclear fragmentation, are good candidates for novice surgeons who want to learn this surgical technique. Patients with hard cataracts and large nuclei are

Outcomes of SLIMCE–K technique

recommended for cataract surgery undergone with an experienced surgeon.

The limitations of this study include a small sample size, a short follow-up period, and the lack of a direct comparison with other cataract surgical techniques, although a comparative study was done between the Kongsap technique and phacoemulsification [12]. A further comparative study of this modified technique, with a long-term follow-up, should be done.

In summary, when performed by an experienced surgeon, SLIMCE-K is a safe and effective procedure as it requires no phacoemulsification machine or sutures, and it provides good visual recovery with a low rate of complications. Further, it can be used for any nuclear grading of cataract hardness that is more common in developing countries.

Acknowledgement: I wish to thank www.editage.com for editing the manuscript.

REFERENCES

- 1 Ruit S, Tabin GC, Nissman SA, Paudyal G, Guring R. Low-cost high-volume extracapsular cataract extraction with posterior chamber intraocular lens implantation in Nepal. *Ophthalmology* 1999;106(10):1887–1892
- 2 Blumenthal M, Ashkenazi I, Assia E, Cahane M. Small-incision manual extracapsular cataract extraction using selective hydrodissection. *Ophthalmic Surg* 1992;23(10):699–701
- 3 Akura J, Kaneda S, Ishihara M. Quarters extraction technique for manual phacofragmentation. *J Cataract Refract Surg* 2000;26(9):1281–1287
- 4 Kongsap P. Cataract surgery using the Nylon loop technique. *Asian J Ophthalmol* 2006;8(4):135–138
- 5 Kongsap P, Wiriyaluppa C. Prechop manual phacofragmentation: cataract surgery without a phacoemulsification machine. *Asian J Ophthalmol* 2002;4:7–9
- 6 Hepşen IF, Cekiç O, Bayramlar H, Totan Y. Small incision extracapsular cataract surgery with manual phacotrisection. *J Cataract Refract Surg* 2000;26 (7): 1048–1051
- 7 Kosakarn P. Manual phacocracking. *Asian J Ophthalmol* 2004;5(4):6–8
- 8 Gutierrez–Carmona FJ. Manual multiphacofragmentation through a 3.2mm clear corneal incision. *J Cataract Refract Surg* 2000;26(10):1523–1528
- 9 Hennig A. Nucleus management with Fishhook. *Indian J Ophthalmol* 2009;57 (1):35–37
- 10 Yao K, Jiang JK, Du XH. Small incision extra–capsular cataract extraction with a manual nucleus division technique and intraocular lens implantation. *Zhonghua Yanke Zazhi* 1994;30(3):164–166
- 11 Kongsap P. Manual sutureless cataract surgery with foldable intraocular lens using the Kongsap technique: the results of 95 cases. *J Med Assoc Thai* 2007;90 (8):1627–1632
- 12 Kongsap P. Corneal endothelial cell loss between the Kongsap manual phacofragmentation and phacoemulsification. *J Med Assoc Thai* 2008;91 (7): 1059–1065
- 13 Lam DS, Rao SK, Fan AH, Congdon NG, Wong V, Liu Y, Lam PT. Endothelial cell loss and surgically induced astigmatism after sutureless large–incision manual cataract extraction (SLIMCE). *Arch Ophthalmol* 2009;127(10):1284–1289
- 14 George R, Rupauliha P, Sripriya AV, Rajesh PS, Vahan PV, Praveen S. Comparison of endothelial cell loss and surgically induced astigmatism following conventional extracapsular cataract surgery, manual small–incision surgery and phacoemulsification. *Ophthalmic Epidemiol* 2005;12(5):293–297
- 15 Hayashi K, Hayashi H, Nakao F, Hayashi F. Corneal endothelial cell loss in phacoemulsification surgery with silicone intraocular lens implantation. *J Cataract Refract Surg* 1996;22(6):743–747
- 16 Chylack LT Jr, Leske MC, McCarthy D, Khu P, Kashiwagi T, Sperduto R. Lens opacities classification system II (LOCS II). *Arch Ophthalmol* 1989;107 (7): 991–997