

Free autologous internal limiting membrane transplantation in the treatment of large macular hole

Fei-Yan Ma^{1,2}, Rui-Jie Xi¹, Peng-Fei Chen¹, Yu-Hua Hao¹

¹Department of Ophthalmology, Second Hospital of Hebei Medical University, Shijiazhuang 050000, Hebei Province, China

²NIMO Ophthalmology Research Institute, Beijing 100176, China

Correspondence to: Yu-Hua Hao. Department of Ophthalmology, Second Hospital of Hebei Medical University, 215 West Heping Road, Shijiazhuang 050000, Hebei Province, China. yuhuasjz@sina.com

Received: 2018-07-10 Accepted: 2019-03-19

Abstract

• We evaluated the clinical efficacy of free internal limiting membrane (ILM) flap transplantation for the treatment of large macular hole over 500 μm in 42 consecutive patients. Quantified evaluation of the post-operative macular anatomy restoration was performed by spectral-domain optical coherence tomography in the 12mo follow-up. The results showed 41 eyes achieved successful closure (97.6%). Postoperative best corrected visual acuity, ellipsoid layer, and external limiting membrane disruption were significantly improved at all follow-up time points. The central foveal thickness was significantly higher at 1mo. We concluded that free ILM flap transplantation proves to be effective to achieve anatomical and functional improvement for the treatment of large macular hole.

• **KEYWORDS:** vitreoretinal disease; macular hole; internal limiting membrane; vitrectomy

DOI:10.18240/ijo.2019.05.24

Citation: Ma FY, Xi RJ, Chen PF, Hao YH. Free autologous internal limiting membrane transplantation in the treatment of large macular hole. *Int J Ophthalmol* 2019;12(5):848-851

INTRODUCTION

Idiopathic macular hole is a common disease that severely damages the central vision. Ever since more and more studies have revealed the role of internal limiting membrane (ILM) in the pathogenesis of macular hole^[1-2], pars plana vitrectomy (PPV) combined with ILM peeling has become a gold standard, with closure rate as high as 90%^[3-5]. ILM peeling is thought to provide good anatomic and functional results in

macular hole by completely releasing the traction forces on the macula and reducing the postoperative epiretinal membrane formation. However risk factors for failed macular hole surgery include the diameter of the hole greater than 500 μm and chronicity of the lesion longer than 1y. Recently, different surgical modification has been made such as compression of the retinal edges during surgery, arcuate retinotomy or inverted ILM flap technique^[6-11] to achieve better surgical outcome.

Morizane *et al*^[12] revealed for the first time the technique of ILM transplantation and proved its efficacy in macular hole closure in 10 eyes. However, their study did not evaluate the microstructural changes in terms of outer retinal layers and its duration of structural recovery.

In this prospective study, we evaluated for the first time the postoperative anatomical outcomes by spectral-domain optical coherence tomography (SD-OCT), and its functional outcome of PPV combined with ILM transplantation.

SUBJECTS AND METHODS

Ethical Approval This was a prospective interventional case study conducted at the Second Hospital of Hebei Medical University over a 35-month period (January 2013 through November 2015). All investigations adhered to the tenets of the Declaration of Helsinki, and Institute Ethics Committee of Hebei Medical University approval was obtained. Each patient was informed about the benefits and risks of the surgery and their written consents were obtained.

Subjects Forty-two eyes of 42 patients with large macular hole diagnosed by SD-OCT were included in the study. All patients underwent ophthalmic examination, including best-corrected visual acuity (BCVA) using the Snellens chart, intraocular pressure (IOP) by Goldmann applanation tonometry, slit-lamp biomicroscopy for lens opacity further graded by Lens Opacities Classifications System II (LOCS II)^[13], and dilated fundus examination, and SD-OCT (Spectralis HRA+OCT, Heidelberg Engineering, Carlsbad, CA, USA). Inclusion criteria were as follows: 1) idiopathic macular hole with minimum base diameter ≥ 500 μm measured by SD-OCT; 2) a minimum follow-up period of 12mo. Exclusion criteria included eyes with refractive errors of more than -6.00 diopters, or with any other retinal diseases, history of ocular surgery or ocular trauma. Follow up was performed on 1, 3, 6 and 12mo postoperatively. The primary efficacy outcome was

visual acuity (VA) and macular closure rate. The secondary efficacy outcome was the ellipsoid layer disruption diameter, external limiting membrane (ELM) disruption and mean central foveal thickness (CFT) on macular hole closure. The disruption in ellipsoid or ELM was characterized by the loss of the back reflection line, and the disruption volume was calculated using ImageJ in reference to the internal caliber in OCT scans.

Surgical Intervention All procedures were performed by the same surgeon (Hao YH). Phacoemulsification and intraocular lens plantation were indicated if any types of lens opacity (posterior subcapsular, nuclear or cortical opacity) was observed with LOCS II grade ≥ 3 . Creation of posterior hyaloid detachment was indicated in cases of stage-3 macular hole, and standard 25 gauge or 23 gauge PPV was performed for all surgical eyes. Nontoxic concentration of 0.25% indocyanine green was used for ILM staining for 20s under fluid^[4]. ILM transplant was created first using pinch and grasp technique with a size big enough to cover the macular hole but still is able to be tucked within the hole. The edges of the macular hole were elevated using microforceps to create a subretinal space into which the flap was inserted with vitreous-side of the ILM up. A 25-gauge soft-tipped flute needle was applied to massage the edge gently and ensure proper positioning of the flap. The infusion was temporarily tuned down (15 mm Hg) during the creation and insertion of the transplant to prevent flap torn by the fluid stream. In very rare cases (only 1 case in this study), light pipe was used to assist the release of ILM flap from the membrane forceps if the transplant flap is firmly stick on the microforceps with the lights illumination tune down as well, to prevent endoillumination-induced maculopathy. The IOP was resumed back to 30 mm Hg and standard ILM (ILM peeling was continued up to the arcades. Fluid gas exchange with 12% perfluoropropane (C3F8) was performed. The patients were advised face down position for 1wk postoperatively starting from the day of surgery (Figure 1).

Statistical Analysis ANOVA was used to compare BCVA, ellipsoid layer disruption, ELM disruption and CFT. All analyses were performed with SPSS 13.0 software and difference was considered to be statistically significant when $P < 0.05$.

RESULTS

Totally forty-two eyes of 42 patients met inclusion criteria and were enrolled in this study. The mean age was 64.5 years old (range 54-76y), and majority of patients were females (83.3%). The mean spherical equivalent was -2.97 D (range +3.50 D to -5.25 D). The mean duration of symptoms was 3.3mo (range 20d-12mo). Three study eyes were diagnosed with stage 3 (7.1%) macular hole and 39 (92.8%) were stage 4.

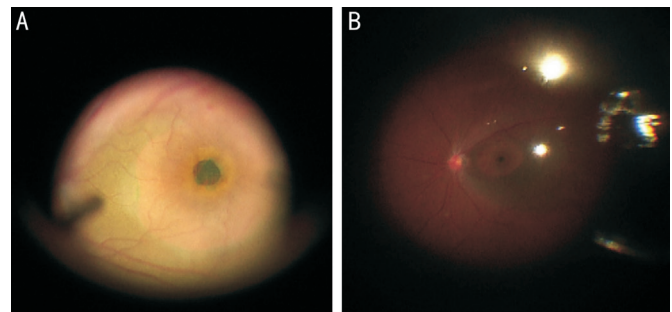


Figure 1 Intraoperative view A: ILM peeling was performed and the free ILM flap was transplanted to cover the base of the macular hole; B: After gas-fluid exchange, the ILM flap was confirmed in place under air view.

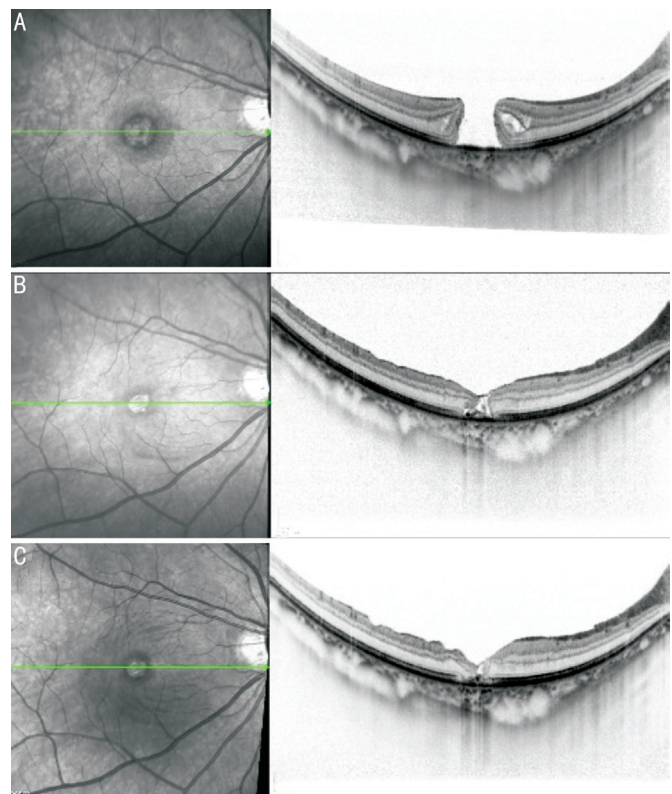


Figure 2 SD-OCT scan of large macular hole pre and post surgery A: Large macular hole with 633 μm edge diameter and 995 μm base diameter; B: At 14d follow-up after PPV+ILM transplantation, SD-OCT scans showed hyper-reflective signal at the base; C: At 3mo follow-up post-operatively, anatomical large macular hole closure was obtained, with resolution of the hyper-reflective signal.

Large Macular Hole Anatomical Closure Rate Preoperative base diameter of macular hole on SD-OCT was $814.3 \pm 112.9 \mu\text{m}$. At 12mo follow-up, 41 eyes achieved complete anatomic closure (97.6%). One eye failed complete closure although with significantly decreased MH diameter. The transplanted ILM flaps presented as highly reflective materials on SD-OCT at 14d postoperatively, but resolved within 3mo (Figure 2).

Best Corrected Visual Acuity Mean baseline BCVA was 1.37 ± 0.05 logMAR, and postoperative mean BCVA was 1.03 ± 0.06 at 1mo ($t=4.782$, $P=0.0001$), 0.802 ± 0.045 at 3mo

($t=3.452$, $P=0.011$), 0.67 ± 0.04 at 6mo ($t=2.236$, $P=0.048$) and 0.51 ± 0.06 at 12mo ($t=2.251$, $P=0.034$). There is significantly improvement of VA postoperatively ($F=28.032$, $P<0.001$).

Ellipsoid Layer Disruption Diameter Mean baseline ellipsoid layer disruption diameter was 1112 ± 45.4 μm , and postoperative ellipsoid layer disruption diameter was 859 ± 84.6 μm at 1mo ($t=2.812$, $P=0.021$), 649 ± 52.5 μm at 3mo ($t=2.414$, $P=0.035$), 486 ± 46.9 μm at 6mo ($t=2.123$, $P=0.044$) and 320 ± 45.1 μm at 12mo ($t=2.178$, $P=0.042$). There is significant anatomic reconstruction of ellipsoid layer structure ($F=38.761$, $P<0.001$).

External Limiting Membrane Disruption Mean baseline ELM disruption diameter was 1038 ± 39.6 μm , and postoperative ELM disruption diameter was 748 ± 64.12 μm at 1mo ($t=3.810$, $P=0.002$), 585 ± 48.9 μm at 3mo ($t=2.111$, $P=0.048$), 438 ± 42.8 μm at 6mo ($t=2.179$, $P=0.042$) and 265 ± 29.0 μm at 12mo ($t=2.545$, $P=0.034$). There is significant anatomic ELM restoration ($F=36.459$, $P<0.01$).

Central Foveal Thickness Postoperative CFT was 239 ± 29.7 μm at 1mo follow-up, but significantly reduced to 174 ± 13.2 μm at 3mo follow-up ($t=3.026$, $P=0.004$), 165 ± 15.8 μm at 6mo ($t=3.324$, $P=0.003$), and 175 ± 30.0 μm at 12mo follow-up ($t=0.214$, $P=0.028$). There is no statistical significance between 3mo and 6mo ($t=0.214$, $P=0.837$), or between 6mo and 12mo ($t=0.193$, $P=0.867$).

DISCUSSION

The role of ILM in the pathogenesis of macular hole has been elucidated in recent studies^[14]. ILM peeling is a way of making sure no remnant vitreous will exert tangential traction over the macula and provide a support for cell proliferation, which will serve as an effective way of prevent the formation of epiretinal membrane. ILM peeling is also aimed at anatomical closure of macular hole by surgically inducing glial cell proliferation. idiopathic MH closure rate is significantly increased (90%) after ILM peeling compared with non-ILM peeling technique (58%)^[14].

However, for macular hole over 500 μm in diameter is still at risk for surgery failure and poor vision prognosis even after PPV+ILM peeling^[15]. Michalewska *et al*^[8] reported for macular holes with a minimum diameter exceeding 500 μm , final VA is usually less than 0.2 and reoperations are sometimes. The success rate of repeated surgeries for large macular hole were lower than primary surgery. The visual comes are usually poorly improved because of the bare retinal pigment epithelium (RPE) for large macular hole.

In recent years, different surgical improvement has been reported to improve better surgical outcome and higher closure rate of large macular hole, including autologous serum or autologous platelet injection, arcuate retinotomy and inverted ILM flap^[3-4,7,12,16]. In our study, we conducted free

ILM flap transplantation for large macular hole, with a good closure rate up to 97.6%, with no severe intraoperatively or postoperatively complications and indocyanine green-toxicity up to 35-month follow-up. The idea behind our surgical design is based on the hypothesis that, first of all the peeling of ILM will serve as a damage to the retina, which will further stimulate the aggregation and migration of macrophages from the vitreous into the vitreoretinal interface, thus inducing glial cell proliferation mediated by α -tumor necrosis factor (α TNF)^[17-20], and secondly the transplanted ILM at the base will provide scaffold for glial cell proliferation^[21].

One possible intraoperative complication is the damage to the RPE at the base of the macular hole. However, the non-inverted ILM serves to be a protection and solution. We highly respect the original orientation of the free ILM flap due to the histology findings that the retinal surface is rougher than the vitreous surface^[22], potentially providing stronger hold to RPE layer and lowering the necessity of too much exertion when exacting submacular fluid during fluid-gas exchange. Up to the 12-month follow-up, no signs of RPE damage (defect or clumping) were observed in SD-OCT scan in our study population.

Even though it has proven in this study that free ILM flap transplantation is effective in achieving anatomic reconstruction and VA improvement in eyes with large macular hole, the real-world visual benefit of such technique still needs to be carefully investigated. In one of our unpublished retrospective comparison study ($n=20$ in each group), postoperative logMAR BCVA in ILM transplant group were 0.67 ± 0.040 at 6mo follow-up, and 0.50 ± 0.062 at 12mo follow-up, while the ILM peeling group were 0.92 ± 0.041 ($t=2.871$, $P=0.007$) and 0.79 ± 0.053 ($t=2.415$, $P=0.027$) respectively, indicating significant visual improvements. Thus a well-conducted large-population based prospective study between the two surgical groups is stilled called for. But but the value of this surgical technique not only lies in its potential clinical efficacy, but also allows us to understand the behavior of autologous ILM scaffold, the process of macular hole close as well as its underlying cellular behavior.

ACKNOWLEDGEMENTS

We would like to express our sincere gratitude to Dr. Jay Chhablani, LV Prasad Eye Institute, Hyderabad, India, for his great effort in proof-reading and improving the originality of English expression, as well as manuscript editing especially in the Methods part.

Foundations: Supported by Hebei Science and Technology Department (Project to Benefit the People No.16277717D); Natural Science Foundation of Hebei Province (No. H2015206249); Second Hospital of Hebei Medical University (No.2h1201508).

Conflicts of Interest: Ma FY, None; Xi RJ, None; Chen PF, None; Hao YH, None.

REFERENCES

- 1 Gass JD. Idiopathic senile macular hole. Its early stages and pathogenesis. *Arch Ophthalmol* 1988;106(5):629-639.
- 2 Gass JD. Reappraisal of biomicroscopic classification of stages of development of a macular hole. *Am J Ophthalmol* 1995;119(6):752-759.
- 3 Haritoglou C, Gass CA, Schaumberger M, Gandorfer A, Ulbig MW, Kampik A. Long-term follow-up after macular hole surgery with internal limiting membrane peeling. *Am J Ophthalmol* 2002;134(5):661-666.
- 4 Ando F, Sasano K, Ohba N, Hirose H, Yasui O. Anatomic and visual outcomes after indocyanine green-assisted peeling of the retinal internal limiting membrane in idiopathic macular hole surgery. *Am J Ophthalmol* 2004;137(4):609-614.
- 5 Beutel J. Internal limiting membrane peeling with indocyanine green or trypan blue in macular hole surgery. *Arch Ophthalmol* 2007;125(3):326.
- 6 Alpatov S, Shchuko A, Malyshev V. A new method of treating macular holes. *Eur J Ophthalmol* 2007;17(2):246-252.
- 7 Charles S, Randolph JC, Neekhra A, Salisbury CD, Littlejohn N, Calzada JI. Arcuate retinotomy for the repair of large macular holes. *Ophthalmic Surg Lasers Imaging Retina* 2013;44(1):69-72.
- 8 Michalewska Z, Michalewski J, Adelman RA, Nawrocki J. Inverted internal limiting membrane flap technique for large macular holes. *Ophthalmology* 2010;117(10):2018-2025.
- 9 Kuriyama S, Hayashi H, Jingami Y, Kuramoto N, Akita J, Matsumoto M. Efficacy of inverted internal limiting membrane flap technique for the treatment of macular hole in high myopia. *Am J Ophthalmol* 2013;156(1):125-131.e1.
- 10 Michalewska Z, Michalewski J, Dulciewska-Cichecka K, Nawrocki J. Inverted internal limiting membrane flap technique for surgical repair of myopic macular holes. *Retina* 2014;34(4):664-669.
- 11 Khodani M, Bansal P, Narayanan R, Chhablani J. Inverted internal limiting membrane flap technique for very large macular hole. *Int J Ophthalmol* 2016;9(8):1230-1232.
- 12 Morizane Y, Shiraga F, Kimura S, Hosokawa M, Shiode Y, Kawata T, Hosogi M, Shirakata Y, Okanouchi T. Autologous transplantation of the internal limiting membrane for refractory macular holes. *Am J Ophthalmol* 2014;157(4):861-869.e1.
- 13 Chylack LT Jr, Leske MC, McCarthy D, Khu P, Kashiwagi T, Sperduto R. Lens opacities classification system II (LOCS II). *Arch Ophthalmol* 1989;107(7):991-997.
- 14 Lois N, Burr J, Norrie J, Vale L, Cook J, McDonald A, Boachie C, Ternent L, McPherson G; Full-thickness Macular Hole and Internal Limiting Membrane Peeling Study (FILMS) Group. Internal limiting membrane peeling versus no peeling for idiopathic full-thickness macular hole: a pragmatic randomized controlled trial. *Invest Ophthalmol Vis Sci* 2011;52(3):1586-1592.
- 15 Ezra E, Gregor ZJ, Morfields Macular Hole Study Ggroup Report No.1. Surgery for idiopathic full-thickness macular hole: two-year results of a randomized clinical trial comparing natural history, vitrectomy, and vitrectomy plus autologous serum: Morfields Macular Hole Study Group Report no. 1. *Arch Ophthalmol* 2004;122(2):224-236.
- 16 Sabti KA, Kumar N, Azad RV. Extended internal limiting membrane peeling in the management of unusually large macular holes. *Ophthalmic Surg Lasers Imaging* 2009;40(2):185-187.
- 17 Martín F, Pastor JC, De La Rúa ER, Mayo-Iscar A, García-Arumí J, Martínez V, Fernández N, Saornil MA. Proliferative vitreoretinopathy: cytologic findings in vitreous samples. *Ophthalmic Res* 2003;35(4):232-238.
- 18 Caicedo A, Espinosa-Heidmann DG, Piña Y, Hernandez EP, Cousins SW. Blood-derived macrophages infiltrate the retina and activate Muller glial cells under experimental choroidal neovascularization. *Exp Eye Res* 2005;81(1):38-47.
- 19 Winkler J, Hagemstein S, Rohde M, Laqua H. Cellular and cytoskeletal dynamics within organ cultures of porcine neuroretina. *Exp Eye Res* 2002;74(6):777-788.
- 20 Fernandez-Bueno I, Pastor JC, Gayoso MJ, Alcalde I, Garcia MT. Müller and macrophage-like cell interactions in an organotypic culture of porcine neuroretina. *Mol Vis* 2008;14:2148-2156.
- 21 De Novelli FJ, Preti RC, Ribeiro Monteiro ML, Pelayes DE, Junqueira Nóbrega M, Takahashi WY. Autologous internal limiting membrane fragment transplantation for large, chronic, and refractory macular holes. *Ophthalmic Res* 2015;55(1):45-52.
- 22 Beyazyildiz Ö, Tirhiş MH, Hekimoğlu ER, Beyazyildiz E, Kaymaz F, Yilmazbaş P, Öztürk F. Histopathological analysis of internal limiting membrane surgically peeled from eyes with epiretinal membrane. *Curr Eye Res* 2016;41(2):258-265.