

# The macular microstructure repair and predictive factors of surgical outcomes after vitrectomy for idiopathic macular hole

Jing-Ling Zou, Jun Zeng

Department of Ophthalmology, the Second Xiangya Hospital, Central South University, Changsha 410011, Hunan Province, China

**Correspondence to:** Jun Zeng. Department of Ophthalmology, the Second Xiangya Hospital, Central South University, Changsha 410011, Hunan Province, China. zengjun001@csu.edu.cn

Received: 2019-01-27 Accepted: 2019-03-07

## Abstract

• To evaluate the macular microstructure repair and explore the factors related to those changes and visual improvement after vitrectomy for idiopathic macular hole (IMH). Totally 19 eyes of 18 IMH patients who underwent macular hole (MH) surgery were evaluated with best-corrected visual acuity (BCVA) and spectral-domain optical coherence tomography (SD-OCT) images. All 19 eyes closed at 6mo postoperatively. BCVA was observed gradually improved ( $P<0.001$ ), with subretinal fluid (SRF) gradually absorbed ( $P=0.021$ ) and the rate of external limiting membrane (ELM) defects gradually decreased ( $P=0.011$ ) with follow-up time. Poorer postoperative logMAR BCVA correlated with larger MH minimum diameter ( $P<0.001$ ), larger MH basal diameter ( $P=0.008$ ), longer symptom duration ( $P=0.002$ ) and poorer preoperative logMAR BCVA ( $P=0.010$ ). More improvement in BCVA correlated only with poorer preoperative in logMAR BCVA ( $P=0.002$ ). The earlier reconstruction of ELM was associated with smaller MH basal diameter ( $P=0.022$ ) and shorter symptom duration ( $P=0.008$ ). In conclusion, smaller basal diameter of MH and shorter symptom duration were key factors in earlier reconstruction of ELM.

• **KEYWORDS:** idiopathic macular hole; macular microstructure; predictive factors

DOI:10.18240/ijo.2019.05.25

**Citation:** Zou JL, Zeng J. The macular microstructure repair and predictive factors of surgical outcomes after vitrectomy for idiopathic macular hole. *Int J Ophthalmol* 2019;12(5):852-857

## INTRODUCTION

After Kelly and Wendel<sup>[1]</sup> first reported successful vitreous surgery for the macular hole (MH), Park *et al*<sup>[2]</sup> reported

internal limiting membrane (ILM) peeling technology and then Michalewska *et al*<sup>[3]</sup> proposed inverted ILM flap technique. Liggett *et al*<sup>[4]</sup> first used autologous serum as an adjuvant to increase the MH closure rate, and serum was deduced that contains numerous growth factors, which can induce fibrocellular migration, adhesion, and proliferation<sup>[5]</sup>. Gas, usually C<sub>3</sub>F<sub>8</sub> or SF<sub>6</sub>, as tamponade materials were widely used in MH surgery. Recently, several studies found that air filling is equivalent to long-effect air tamponade in MH surgery<sup>[6-8]</sup>. With the rapid development of MH surgery technique, the closure rate of MH surgery already reached more than 90%<sup>[9-10]</sup>. Since spectral-domain optical coherence tomography (SD-OCT) has been used to observe the macular microstructure, the fine changes in the process of MH reconstruction are being detected. Grewal *et al*<sup>[11]</sup> found the size of foveal lucency correlated with visual recovery and preoperative basal hole diameter was related to foveal lucency. Liu *et al*<sup>[12]</sup> reported that macular hole closure index (MHCI) was a new predictive method for anatomical outcomes after IMH surgery. Shpak *et al*<sup>[13]</sup> suggested preoperative central subfield retinal thickness could predict postoperative anatomical results of IMH. Kitao *et al*<sup>[14]</sup> have reported that the time until external limiting membrane (ELM) bridge and the glial cell disappearance were associated with postoperative best-corrected visual acuity (BCVA) at 3y, which indicates that ELM maybe a crucial early predictive factor to visual improvement. However, the predictive factors of visual improvement are still controversial and the relevant elements to the macular microstructure repair process are still unclear. The purpose of this study was to explore the macular microstructure changes after vitrectomy for idiopathic macular hole (IMH) and investigate the correlative predictive factors to visual improvement and macular microstructure repair for MH surgery.

## SUBJECTS AND METHODS

**Ethical Approval** This was a retrospective study. The study was approved by the Second Xiangya Hospital Ethics Committee and conducted in accordance with the Declaration of Helsinki. All patients were informed about the risks and benefits of the surgery, and written informed consent was obtained in accordance with the guidelines for the Second Xiangya Hospital of Central South University.

The medical records of 19 eyes of 18 patients with an IMH who were underwent surgery in the Second Xiangya Hospital between October 2016 and April 2018 were reviewed. All patients included had been diagnosed with a stage 2, 3 or 4 IMH according to the Gass classification<sup>[15]</sup>. We excluded eyes with retinal detachment, glaucoma, diabetic retinopathy, high myopia, follow-up length less than 6mo postoperatively or any other secondary MHs. All patients had a standard ophthalmological examination before and 1wk, 1, 3, 6mo after surgery. Examinations included BCVA, binocular indirect ophthalmoscopy, slit-lamp bio-microscopy and SD-OCT. One surgeon (Zeng J) operated on all eyes under local anesthesia.

Standard 23-gauge pars plana vitrectomy was performed for all MHs. Before surgery, two to three milliliters blood from patients of MH were collected in a syringe and kept it in a vertical and static position for more than 30min. Triamcinolone acetonide (TA) was used to clarify the vitreous gel. Eighteen of 19 patients of MH underwent phacoemulsification. After core vitrectomy, posterior vitreous detachment was performed. Indocyanine green (ICGI; 0.125%) was used for ILM staining. The ILM was peeled around vascular arch. Peeling cases then give gas-fluid exchange and intraocular lens implantation directly. For inverted ILM flap cases, the ILM around macular about one to two papillary diameter (PD) was inverted into MH so that it completely covered and filled the MHs. Next, serum was extracted gently from the post-static stratified blood and has been intravitreal injection about 0.05 mL. Gas-fluid change was given slightly to prevent the flapped ILM shifting. Intraocular lens implantation was performed. All the patients were instructed to remain face-down position for 3 to 5d postoperatively. SD-OCT was used to confirm whether the MH closed and detect the macular microstructure changes. The glial proliferation was defined as the presence of a foveal hyperreflective lesion on SD-OCT based on the previous reports of histopathologic studies of autopsy eyes and OCT images of surgically closed MHs<sup>[16-17]</sup>.

For statistical analysis, logMAR BCVA and central retinal thickness (CRT) were analyzed using a one-way analysis of variance (ANOVA) when quantitative parameters were compared among baseline, postoperative 1wk, 1, 3 and 6mo. If the parameter was not normally distributed, the non-parametric Kruskal-Wallis one-way ANOVA on ranks was applied. Fisher's exact test was performed to test the existent subretinal fluid (SRF), ELM defects, retinal nerve fiber layer (RNFL) defects, internal plexiform layer (IPL) defects and the closure of MH at postoperative 1wk, 1, 3 and 6mo. Correlations between preoperative parameters and postoperative visual acuity were analyzed with Spearman's ranked correlation. Independent-samples *t*-test was used to analysis the influential factors between the continuous ELM and ELM defects. All

analyses were conducted using SPSS (Version 19.0, USA), and  $P < 0.05$  was deemed to indicate statistical significance.

## RESULTS

The retrospective study was comprised of 19 eyes of 18 patients. Totally 19 of 19 the MHs closed successfully at postoperative 6mo. The 19 cases consisted of 17 (89%) women and 2 (11%) men ranging in age from 49 to 74y with an average age of  $64.0 \pm 5.4$ y. The operated eye was the right eye in 11 patients (58%) and left eye in 8 patients (42%). All patients were phakic eyes before surgery, and 18 (95%) of them underwent phacoemulsification and foldable lens implantation during surgery. Preoperative mean logMAR BCVA was  $1.3 \pm 0.48$ . The MHs were classified as stage 2 in 8 eyes (42%), stage 3 in 9 eyes (47%) and stage 4 in 2 eyes (11%) preoperatively. The mean axial length was  $23 \pm 0.65$  mm (range, 22.06-24.61 mm). Mean preoperative minimum diameter of the holes was  $430 \pm 169$   $\mu$ m (range, 177-780  $\mu$ m). Mean preoperative basal diameter of the holes was  $763 \pm 228$   $\mu$ m (range, 304-1165  $\mu$ m). Symptom duration was  $6.0 \pm 7.1$ mo (range, 0.5-24).

Changes in logMAR BCVA are shown in Table 1, which suggested that postoperative BCVA continuously increased over 6mo ( $P < 0.001$ ). Totally 19 operated eyes (100%) observed were anatomically closed detected by OCT at postoperative 1mo. It was observed that ELM reconstructed earlier compared to the reconstruction of the ellipsoid zone (EZ) and cone interdigitation zone (CIZ; Figure 1). At 1wk, 1, 3, 6mo postoperatively, ELM defects were seen in 18 eyes (95%), 15 eyes (79%), 13 eyes (68%), 9 eyes (47%), respectively ( $P = 0.011$ ). EZ defects, CIZ defects were observed in all the eyes during all the follow-up period. During this process, the ELM was concomitantly reconstructed with the length of EZ defects and CIZ defects shorten showed in Figure 1. The area of the RNFL defects were observed in 11 eyes (63%) at 1wk, 15 eyes (84%) at 1mo, 18 eyes (95%) at 3mo and 18 eyes (95%) at 6mo postoperatively. The IPL defects were observed earliest at 1mo with 2 eyes (11%), and then 6 eyes (32%) at 3mo, 7 eyes (37%) at 6mo postoperatively.

Poorer postoperative logMAR BCVA correlated with larger MH minimum diameter ( $P < 0.001$ ), larger MH basal diameter ( $P = 0.008$ ), longer symptom duration ( $P = 0.002$ ) and poorer preoperative logMAR BCVA ( $P = 0.010$ ). More improvement in BCVA correlated only with poorer preoperative in logMAR BCVA ( $P = 0.002$ ). But improvement in BCVA has no correlation with symptom duration, MH minimum diameter and basal diameter. As for the change in age, it has no correlation with both postoperative logMAR BCVA and improvement in logMAR BCVA (Table 2).

In addition, it was found that cases with continued ELM at 6mo postoperatively had smaller MH basal diameter ( $P = 0.022$ )

**Table 1 Postoperative time-dependent changes in logMAR BCVA and foveal microstructure**

Parameters	1wk	1mo	3mo	6mo	<i>n</i> (%)
logMAR BCVA, (mean±SD)	0.96±0.34	0.81±0.26	0.65±0.25	0.54±0.22	<0.001
CRT, μm (mean±SD)	200±74	183±74	177±70	186±61	0.781
Presence of SRF	9 (47)	4 (21)	3 (16)	1 (5)	0.019
ELM defects	18 (95)	15 (79)	13 (68)	9 (47)	0.010
EZ defects	19 (100)	19 (100)	19 (100)	19 (100)	1.0
CIZ defects	19 (100)	19 (100)	19 (100)	19 (100)	1.0
Glial proliferation	16 (84)	19 (100)	19 (100)	19 (100)	1.0
Inner retinal defects					
RNFL defects	11 (63)	15 (84)	18 (95)	19 (100)	0.002
IPL defects	0	2 (11)	6 (32)	7 (37)	0.006
Closure	17 (89)	19 (100)	19 (100)	19 (100)	0.240

logMAR BCVA: Logarithm of the minimum angle of resolution best-corrected visual acuity; CRT: Central retinal thickness; SRF: Subretinal fluid; ELM: External limiting membrane; EZ: Ellipsoid zone; CIZ: Cone interdigitation zone; RNFL: Retinal nerve fiber layer; IPL: Internal plexiform layer.

**Table 2 Correlation between preoperative parameters and logMAR BCVA**

Parameters	Mean±SD (range)	Postoperative logMAR BCVA at 6mo		Change in logMAR BCVA	
		Correlation	<i>P</i> <sup>b</sup>	Correlation	<i>P</i> <sup>b</sup>
MH size (minimum diameter)	430±169 (177-780)	0.721	<0.001 <sup>a</sup>	0.104	0.672
MH size (basal diameter)	763±228 (304-1165)	0.590	0.008 <sup>a</sup>	0.144	0.556
Preoperative logMAR BCVA	1.3±0.48 (0.7-2.4)	0.574	0.010 <sup>a</sup>	0.655	0.002 <sup>a</sup>
Symptom duration, mo	6.0±7.1 (0.5-24)	0.655	0.002 <sup>a</sup>	-0.207	0.396
Age, y	64.0±5.4 (49-74)	-0.082	0.739	-0.098	0.690

logMAR BCVA: Logarithm of the minimum angle of resolution best-corrected visual acuity; MH: Macular hole. <sup>a</sup>Statistically significant correlation (*P*<0.05); <sup>b</sup>Independent-samples *t*-test.

**Table 3 BCVA (logMAR) and ELM reconstruction at 6mo after surgery**

Parameters	ELM reconstruction at postoperative 6mo		<i>P</i> <sup>b</sup>
	Continuous ( <i>n</i> =10)	ELM defects ( <i>n</i> =9)	
Eyes, <i>n</i> (%)	10 (53)	9 (47)	
Postoperative logMAR BCVA at 6mo	0.45±1.86	0.64±0.23	0.061
Preoperative logMAR BCVA	1.01±0.35	1.21±0.43	0.291
Mean difference in logMAR BCVA	0.57±0.31	0.57±0.39	0.975
MH size (minimum diameter)	383.19±125.89	481.72±211.02	0.227
MH size (basal diameter)	650.80±216.37	888.22±193.30	0.022 <sup>a</sup>
Symptom duration, mo	2.05±1.64	10.33±8.64	0.008 <sup>a</sup>
Age, y	62.60±6.19	65.89±4.11	0.195

logMAR BCVA: Logarithm of the minimum angle of resolution best-corrected visual acuity; ELM: External limiting membrane; MH: Macular hole; <sup>a</sup>Statistically significant correlation (*P*<0.05); <sup>b</sup>Independent-samples *t*-test.

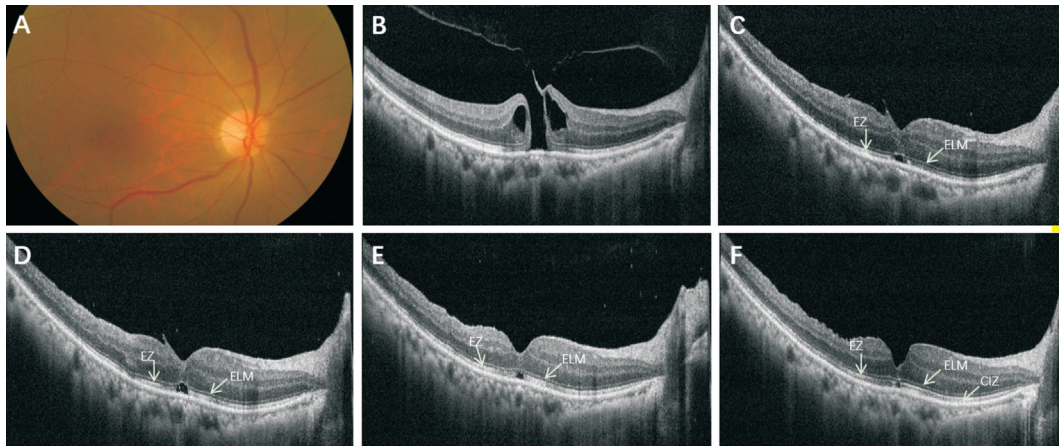
and shorten symptom duration (*P*=0.008). But there were not differences in age, MH minimum diameter, preoperative in logMAR BCVA, postoperative logMAR BCVA and change in logMAR BCVA (Table 3).

**DISCUSSION**

In this study, we aimed to investigate OCT-measured microstructure characteristics in fovea post MH surgery and relevant predictive factors to visual improvement and macular microstructure features.

SRF was a common appearance after successful MH surgery<sup>[18]</sup>. But the exact effects of SRF on surgical outcomes of MH

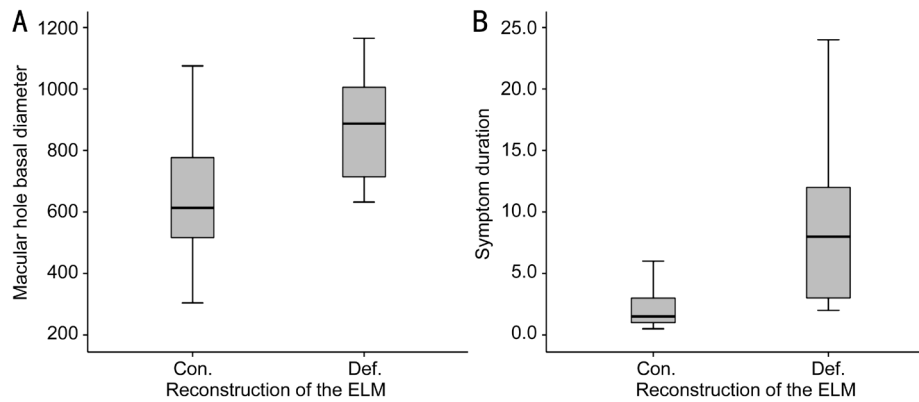
were still controversial. Zambarakji *et al*<sup>[19]</sup> had reported that cases with SRF had bad effects on visual or IS/OS outcomes after successful MH surgery. On the contrary, Tranos *et al*<sup>[18]</sup> observed that the presence of SRF was not related to worse outcomes. In our study, we found that postoperative SRF absorbed with the follow-up time. It should be noted that our study observed that the main SRF disappearance period was in the first 3mo after surgery. The closure of MHs was observed on OCT within postoperative 1wk in most successful cases. In present study, CRT was 200±74 μm at postoperative 1wk. Then it has a decreasing period and a gentle increase, and



**Figure 1** A 63 years old female with 1mo symptom duration A: Preoperative color fundus photo image of the MH; B: The SD-OCT showed a full-thickness stage 2 MH (398  $\mu$ m). The logMAR BCVA was 0.92. C: At postoperative 1wk, the ELM appeared to be continuous with moderately reflective dots. There was a disruption of the EZ and CIZ. The SRF in the fovea looked like a cystic space was also presented. The logMAR BCVA was 0.6. D-F: At postoperative 1mo (D), 3mo (E), and 6mo (F), the morphology of the fovea improved persistently with the absorption of SRF, the shorten of CIZ and EZ defects, the reduction of glial proliferation (the hyperreflective dots in fovea). All these changes were accompanied by visual improvements to 0.6, 0.4, and 0.22 respectively.

develop into  $186 \pm 61 \mu\text{m}$  at postoperative 6mo. Takamura *et al*<sup>[20]</sup> suggested that postoperative CRT was associated with visual outcomes. But it is difficult to ensure the precise measurement to CRT considering all those values were measured manually. The reconstruction of ELM, EZ and CIZ represents the integrity of the photoreceptor layer. In our study, ELM reconstruction completed earliest compared to EZ and CIZ and the reconstruction of EZ and CIZ have not completed at postoperative 6mo but with the length of EZ defects and CIZ defects shortened (Figure 1). It suggested that macular microstructure repair was step by step and mostly more than 6mo. After MH surgery, there were some arcuate striae observed in the field of ILM peeling, which was named dissociated optic nerve fiber layer (DONFL)<sup>[21]</sup>. The DONFL appearance was found correlate with RNFL defects and IPL defects, which maybe caused by the irreversible damage to the part of the Müller cell during the process of peeling ILM<sup>[21]</sup>. It was deemed that the appearance of those defects had no effects on visual improvement<sup>[22]</sup>, but Sabry *et al*<sup>[23]</sup> found that concentric macular dark spots (CMDS) was correlated to RNFL defects. In present study, the RNFL defects and IPL defects were also seen and which became evidently with the follow-up time and the appearance of the IPL defects later than the RNFL defects. Meanwhile, the RNFL defects appeared slightly at the beginning, and then became deeper and wider with the follow-up time. Similar performance also showed in study observed by Runkle *et al*<sup>[24]</sup>. The rate of RNFL defects was evident and observed in all eyes postoperatively in Sabry *et al*'s<sup>[23]</sup> study. As for the study of the predictive factors, there were still controversial. Goker *et al*<sup>[25]</sup> reported that duration of hole symptom, Gass stage and preoperative BCVA did not find

to affect visual outcome. Kim *et al*<sup>[26]</sup> found that choroidal thickness and MH basal diameter were significant predictors of visual improvement, but there were not significant differences between final visual acuity and preoperative visual acuity, hole size, sex or age. Table 2 showed correlations between preoperative parameters and logMAR BCVA. In present study, it suggested that postoperative logMAR BCVA at 6mo had significantly positive correlation with MH minimum diameter ( $P < 0.001$ ) and symptom duration ( $P = 0.002$ ). Also, there were positive correlations between postoperative logMAR BCVA and preoperative logMAR BCVA ( $P = 0.01$ ), postoperative logMAR BCVA and basal diameter ( $P = 0.008$ ). Contrary to Kim *et al*'s<sup>[26]</sup> study, there was a positive correlation between postoperative logMAR BCVA and MH minimum diameter. In former studies, Kazmierczak *et al*<sup>[27]</sup> reported that IS/OS junction defects correlated with the diameter of the MH and the presence of ELM defects were the reason of inferior BCVA. In our study, we found that more improvement in BCVA correlated with poorer preoperative in logMAR BCVA ( $P = 0.002$ ), but have negatives results in symptom duration, MH minimum diameter and basal diameter. It suggested that MH minimum diameter and symptom duration are good predictive factors to longtime visual improvement. Moreover, it was found that cases with continued ELM at 6mo postoperatively had smaller MH basal diameter ( $P = 0.022$ ) and shorten symptom duration ( $P = 0.008$ ; Table 3, Figure 2). As we all known, the integrity of outer retina is key to visual outcomes. ELM restored earliest than IS/OS, that means that only after ELM completed its reconstruction, can IS/OS become continuous. As for MH basal diameter, it is the base of the disruption of hole, also the beginning of outer retina



**Figure 2** Boxplot diagram showed that the MH basal diameter in cases with continuous ELM (Con.) bigger than cases with ELM defects (Def.) at postoperative 6mo (A;  $P=0.022$ ) and the symptom duration of cases with continuous ELM longer than cases with ELM defects at postoperative 6mo (B;  $P=0.008$ ).

restoration. Kitao *et al*<sup>[14]</sup> had reported that there was significant correlation between the time until ELM reconstruction and postoperative BCVA at 3y. Thus, it suggested that basal diameter of MH maybe a crucial factor to final visual acuity. Apart from that, it was also found that cases with continued ELM at 6mo postoperatively had shorten symptom duration. It indicated that symptom duration played an important role in visual outcome. Anatomically, shorten symptom duration was benefit to the early restoration of macular microstructure, which also contributed to visual improvement.

One of the limitations of the present study was small number of patients. Further studies are needed to confirm our results. In addition, we only applied one examination to detect the repair of MHs. It needs more examinations including microperimetry, electroretinogram or OCT angiography to has a more comprehensive exploration about the repair process and predictive factors of MHs.

In conclusion, ELM reconstruction completed earliest compared to EZ and CIZ in the process of macular microstructure repair after successful MH surgery. Preoperative BCVA, symptom duration, minimum diameter and basal diameter of MH were important predictive factors for visual improvement. The MH basal diameter and symptom duration were key factors in early reconstruction of ELM.

**ACKNOWLEDGEMENTS**

**Conflicts of Interest:** Zou JL, None; Zeng J, None.

**REFERENCES**

1 Kelly NE, Wendel RT. Vitreous surgery for idiopathic macular holes. Results of a pilot study. *Arch Ophthalmol* 1991;109(5):654-659.  
 2 Park DW, Sipperley JO, Sneed SR, Dugel PU, Jacobsen J. Macular hole surgery with internal-limiting membrane peeling and intravitreal air. *Ophthalmology* 1999;106(7):1392-1398.  
 3 Michalewska Z, Michalewski J, Adelman RA, Nawrocki J. Inverted internal limiting membrane flap technique for large macular holes. *Ophthalmology* 2010;117(10):2018-2025.  
 4 Liggett PE, Skolik DS, Horio B, Saito Y, Alfaro V, Mieler W. Human

autologous serum for the treatment of full-thickness macular holes. A preliminary study. *Ophthalmology* 1995;102(7):1071-1076.

5 Saito Y, Tano Y. Intraoperative adjunctive agents in vitrectomy: serum, cytokines, and glue. *Semin Ophthalmol* 2000;15(1):36-43.

6 Hasegawa Y, Hata Y, Mochizuki Y, Arita R, Kawahara S, Kita T, Noda Y, Ishibashi T. Equivalent tamponade by room air as compared with SF<sub>6</sub> after macular hole surgery. *Graefes Arch Clin Exp Ophthalmol* 2009;247(11):1455-1459.

7 Usui H, Yasukawa T, Hirano Y, Morita H, Yoshida M, Ogura Y. Comparative study of the effects of room air and sulfur hexafluoride gas tamponade on functional and morphological recovery after macular hole surgery: a retrospective study. *Ophthalmic Res* 2013;50(4):227-230.

8 Chen X, Yao Y, Hao XL, Liu XC, Liu TC. A comparative study of vitrectomy combined with internal limiting membrane peeling for the treatment of idiopathic macular hole with air or C<sub>3</sub>F<sub>8</sub> intraocular tamponade. *J Ophthalmol* 2018;2018:1672501.

9 Ota H, Kunikata H, Aizawa N, Nakazawa T. Surgical results of internal limiting membrane flap inversion and internal limiting membrane peeling for macular hole. *PLoS One* 2018;13(9):e0203789.

10 Chow DR, Chaudhary KM. Optical coherence tomography-based positioning regimen for macular hole surgery. *Retina* 2015;35(5):899-907.

11 Grewal DS, Reddy V, Mahmoud TH. Assessment of foveal microstructure and foveal lucencies using optical coherence tomography radial scans following macular hole surgery. *Am J Ophthalmol* 2015;160(5):990-999.e1.

12 Liu PP, Sun YY, Dong CY, Song D, Jiang YR, Liang JH, Yin H, Li XX, Zhao MW. A new method to predict anatomical outcome after idiopathic macular hole surgery. *Graefes Arch Clin Exp Ophthalmol* 2016;254(4):683-688.

13 Shpak AA, Shkvorchenko DO, Sharafetdinov IKh, Yukhanova OA. Predicting anatomical results of surgical treatment of idiopathic macular hole. *Int J Ophthalmol* 2016;9(2):253-257.

14 Kitao M, Wakabayashi T, Nishida K, Sakaguchi H, Nishida K. Long-term reconstruction of foveal microstructure and visual acuity after idiopathic macular hole repair: three-year follow-up study. *Br J Ophthalmol* 2019;103(2):238-244.

- 15 Gass JD. Idiopathic senile macular hole. Its early stages and pathogenesis. *Arch Ophthalmol* 1988;106(5):629-639.
- 16 Rosa RH Jr, Glaser BM, de la Cruz Z, Green WR. Clinicopathologic correlation of an untreated macular hole and a macular hole treated by vitrectomy, transforming growth factor-beta 2, and gas tamponade. *Am J Ophthalmol* 1996;122(6):853-863.
- 17 Ko TH. Ultrahigh-resolution optical coherence tomography of surgically closed macular holes. *Arch Ophthalmol* 2006;124(6):827.
- 18 Tranos PG, Stavrakas P, Vakalis AN, Asteriadis S, Lokovitis E, Konstas AG. Persistent subretinal fluid after successful full-thickness macular hole surgery: prognostic factors, morphological features and implications on functional recovery. *Adv Ther* 2015;32(7):705-714.
- 19 Zambarakji HJ, Schlottmann P, Tanner V, Assi A, Gregor ZJ. Macular microholes: pathogenesis and natural history. *Br J Ophthalmol* 2005;89(2):189-193.
- 20 Takamura Y, Tomomatsu T, Matsumura T, Arimura S, Gozawa M, Takihara Y, Inatani M. Correlation between central retinal thickness after successful macular hole surgery and visual outcome. *Jpn J Ophthalmol* 2015;59(6):394-400.
- 21 Tadayoni R, Paques M, Massin P, Mouki-Benani S, Mikol J, Gaudric A. Dissociated optic nerve fiber layer appearance of the fundus after idiopathic epiretinal membrane removal. *Ophthalmology* 2001;108(12):2279-2283.
- 22 Demirel S, Abdullayev A, Yanık Ö, Batioğlu F, Özmert E. Evaluation of ganglion cell-inner plexiform layer thickness after vitreoretinal surgery with internal limiting membrane peeling in cases with idiopathic macular hole. *Turk J Ophthalmol* 2017;47(3):138-143.
- 23 Sabry D, El-Kannishy A, Kamel R, Abou Samra W. Correlation between en face optical coherence tomography defects of the inner retinal layers and ganglion cell inner plexiform layer analysis after internal limiting membrane peeling for idiopathic full-thickness macular hole. *Invest Ophthalmol Vis Sci* 2016;57(9):OCT444-OCT450.
- 24 Runkle AP, Srivastava SK, Yuan A, Kaiser PK, Singh RP, Reese JL, Ehlers JP. Factors associated with development of dissociated optic nerve fiber layer appearance in the pioneer intraoperative optical coherence tomography study. *Retina* 2018;38(Suppl 1):S103-S109.
- 25 Goker YS, Koc M, Yuksel K, Yazici AT, Demir A, Gunes H, Ozpinar Y. Relationship between peeled internal limiting membrane area and anatomic outcomes following macular hole surgery: a quantitative analysis. *J Ophthalmol* 2016;2016:5641273.
- 26 Kim SH, Kim HK, Yang JY, Lee SC, Kim SS. Visual recovery after macular hole surgery and related prognostic factors. *Korean J Ophthalmol* 2018;32(2):140-146.
- 27 Kaźmierczak K, Stafiej J, Stachura J, Żuchowski P, Malukiewicz G. Long-term anatomic and functional outcomes after macular hole surgery. *J Ophthalmol* 2018;2018:3082194.