

Effects of intravitreal conbercept before panretinal photocoagulation on lipid exudates in diabetic macular documented by optical coherence tomography

Jing-Rong Shi¹, Quan Zhang^{1,2}, Ting Zhang^{1,3}, Hong Zhuang^{1,3}, Zhong-Cui Sun^{1,3}, Yao-Wu Qin^{1,3}

¹EENT Hospital, Fudan University, Shanghai 200031, China

²Hainan (Boao) International Eye Hospital, Qionghai 571400, Hainan Province, China

³Shanghai Key Laboratory of Visual Impairment and Restoration, Shanghai 200031, China

Correspondence to: Yao-Wu Qin. EENT Hospital, Fudan University, 83# Fengyang Road, Shanghai 200031, China. qinyaowu715@126.com

Received: 2019-05-22 Accepted: 2019-08-14

Abstract

• **AIM:** To evaluate the effects of intravitreal conbercept (IVC) as adjunctive treatments before panretinal photocoagulation (PRP) to decrease hyperreflective dots (HRDs) in Chinese proliferative diabetic retinopathy (PDR) patients.

• **METHODS:** Fifty-nine enrolled patients were categorized into 2 groups: single dose IVC (0.5 mg/0.05 mL) 1wk before PRP (Plus group) or PRP only (PRP group). Six months later, we measured the best corrected visual acuity (BCVA), central macula thickness (CMT) by optical coherence tomography and counted the number of HRDs in different retina layers.

• **RESULTS:** The average CMT significantly decreased in Plus group but increased in PRP group. The average BCVA in the Plus group was also significantly better than that in the PRP group. Total HRDs decreased in the Plus group but increased in PRP group significantly. IVC pre-treatment has beneficial effects on reducing HRDs forming in the inner retina layer while the PRP alone increased the HRDs in the outer retina layer.

• **CONCLUSION:** IVC is a promising adjunctive treatment to PRP in the treatment of PDR. Single dose IVC one week before PRP is suggested to improve retina blood-retina barrier, decrease lipid exudate and inhibit HRDs development in PDR.

• **KEYWORDS:** conbercept; hyperreflective dots; panretinal photocoagulation; proliferative diabetic retinopathy

DOI:10.18240/ijo.2020.04.12

Citation: Shi JR, Zhang Q, Zhang T, Zhuang H, Sun ZC, Qin YW. Effects of intravitreal conbercept before panretinal photocoagulation

on lipid exudates in diabetic macular documented by optical coherence tomography. *Int J Ophthalmol* 2020;13(4):606-613

INTRODUCTION

Diabetic retinopathy (DR) is considered to be one of the prime reasons of visual impairment and blindness. Visual impairment has been found to be correlated with the deposition of hard foveal exudates (HE) which are one of the most common signs in the early stage of DR^[1-2]. In the current research on DR, panretinal photocoagulation (PRP) is currently the main treatment for proliferative diabetic retinopathy (PDR)^[3]. PRP can avoid serious visual impairment and is also a destructive operation with multiple side effects. Studies have shown that severe diabetic macular edema (DME) and impaired vision occur in 25 to 43 percent of PDR patients treated with PRP^[4-5]. In clinic, it is not uncommon that heavy HE developed significantly 3-6mo after PRP treatment in PDR. A large amount of HEs in the macula not only has difficulty in treatment but also a risk of serious vision loss^[6].

Pathologically, HEs are mainly lipid residues of serous exudation of damaged capillaries which composed of lipid-laden macrophages or noncellular materials, such as lipid and proteinaceous substances^[7-8]. The damage of blood-retina barrier (BRB) usually occurs in the early stage of diabetic patients, even before the retinopathy appears^[9-10]. Compared with other indicators such as the course of diabetes, HbA1c and blood pressure, BRB has a stronger ability to predict the progression of DR and DME^[11]. The retinal lesions that develop after PRP have been shown to aggravate the dysfunction of BRB^[12-13]. Vascular endothelial growth factor (VEGF) is known to increase the permeability of blood vessels. As detected in DR, it also has been shown to induce rupture of BRB in both animals and humans^[14-15]. PRP increased VEGF expression and induced BRB dysfunction^[16]. PRP may exasperate the breakdown of BRB in PDR by folded VEGF and induced robust HE formation, especially in patients with higher serum lipid.

Hyperreflective dots (HRDs) in spectral domain-optical coherence tomography (SD-OCT) were considered as precursors and cell components of HE^[17-18]. In fact, before the

ophthalmoscopy found HE, we can determine the degree of lipid exudation caused by BRB decomposition by seeing these micro-exudates clearly in SD-OCT. The parameters based on SD-OCT is helpful to study the effects and therapeutic effects of diabetic retinal physiology. Conbercept is an anti-VEGF recombinant fusion protein that approved by the China State Food and Drug Administration in December 2013. So, in this study, we aimed to exam that if intravitreal conbercept (IVC) pre-treatment before PRP could stabilize BRB and therefore to inhibit HE formation in PDR.

SUBJECTS AND METHODS

Ethical Approval The study protocol was adhered to the tenets of the Declaration of Helsinki and approved by the Review Board and Ethical Committee of the EENT Hospital. All patients had been fully informed of the purpose and methods of the present study and provided written informed consent from themselves or their guardians.

Patients Enrollment This was a retrospective study implemented at the DR Outpatient Center of the EENT Hospital affiliated to Fudan University (Shanghai, China). We reviewed all of with or without the clinically significant macular edema (CSME or NCSME) the type II diabetes PDR patients' medical records, who received PRP alone or with initial IVC between March, 2015 and March, 2018, and had at least 6mo of follow-up. One week before operation, the Plus group eyes received single dose IVC treatment, while the PRP group eyes only received PRP treatment. The choice of patient depends on the patient's condition and willingness. Blood pressure, >8h of fasting blood samples were collected to analyze renal profiles, HbA1c, blood glucose, and lipids (total, low density lipoprotein, high density lipoprotein cholesterol and triglycerides). Ophthalmic examination includes intraocular pressure (IOP), best corrected visual acuity (BCVA), presence of lens opacities, fundus examination. Fundus fluorescein angiography (FFA; TRC.50DX, TOPCON, Japan) checks if necessary to determine the DR level. The criteria for inclusion were >18 years of age, PDR risk is mild to high, and logMAR of BCVA was 0.1-1.0. Exclusion criteria included chronic renal failure, systolic and diastolic blood pressures above 160 and 90 mm Hg, HbA1c levels above 8.5%, major operation or anti-VEGF therapy or systemic steroid within 6mo. Patients with serious HE patch within a radius of 1500 microns in the fovea and other patients with ocular problems, which might limited visual acuity and analysis on OCT images in this study because of macular edema were also excluded. We also ruled out the patients has a history of DME, intraocular surgery, PRP or focal/grid laser photocoagulation, and patients with inadequate clinical record or interruption of treatment.

Treatment The Plus group received IVC (0.5 mg/0.05 mL) 1wk prior to the first PRP session. All enrolled eyes planned to

receive scattered laser treatment with 532 nm argon green laser (Vision one, Lumenis Inc., USA) at 3-4 time points within 3mo (2wk intervals). Each episode is given 400-500 μm points of treatment. If PRP cannot be performed due to increased vitreous hemorrhage (VH), the interval will be prolonged. Pars plana vitrectomy (PPV) would be arranged for and excluded when patients appeared dense VH.

Follow-up Protocol PRP was followed up 1d after injection from 1 to 6mo after initial treatment. Follow-up included BCVA measurement, fundus examination, IOP, slit lamp biomicroscopy and OCT.

Optical Coherence Tomography Examination and Interpretation Spectralis OCT for SD-OCT images (OCT, Heidelberg, Spectralis OCTplus+ Multicolor, Germany). The same retina scanning area was obtained by using the integrated follow-up mode. The SD-OCT images were analyzed 6mo before and after the first PRP. The number of patients with different OCT modes of DME (sponge-like swelling/cystoid macular edema/neuroretinal detachment/mixed type) and abnormal vitreoretinal interface and the existence of the desorganization of retinal inner layers (DRIL) in the fovea with a radius of 1500 μm were recorded. The central macula thickness (CMT) automatically calculates the average retinal thickness within a 500- μm radius central circle on fovea-spanning horizontal raster scan.

Hyperreflective Dots on Spectral Domain-Optical Coherence Tomography HRDs is a discrete but well-defined particulates on SD-OCT that has the same or higher reflectivity as the retinal pigment epithelium (RPE) band, usually 20 to 40 μm in diameter^[18-19]. HRD is a discrete but well-defined particulates on SD-OCT that has the same or higher reflectivity as the RPE band, usually 20 to 40 μm in diameter (<http://imagej.nih.gov/ij/>; provided in the public domain by the National Institutes of Health, Bethesda, MD, USA). Taken the average of HRDs on horizontal and vertical raster scan were taken into statistical analysis. HRDs are divided into three categories according to the different layers of the retina: inner retina, outer retina, and subretinal fluid layer (SRF; Figure 1).

Statistical Analysis SPSS statistical software was used to analyze the results (version 11.0 for Windows; SPSS, Inc., Chicaco, Illinois, USA). Before statistical analysis, vision was converted to logarithmic mean, with $P < 0.05$ considered statistically significant. HRDs, BCVA and CMT, paired *t*-test and other indicators were used to evaluate the difference between baseline examination and 6-month follow-up. Intra-class correlation coefficient (ICC) analysis was used to evaluate the repeatability of HRDs counting between two different observers.

RESULTS

Patients Characteristics at Baseline Finally, a total of 33 eyes with CSME and 26 eyes with NCSME (all 26 eyes with

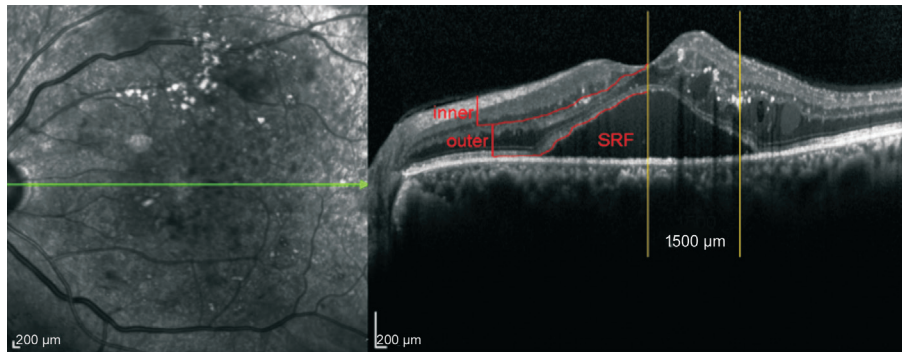


Figure 1 The retina is divided into three different layers: inner retina (from internal limiting membrane to the junction of inner nuclear layer and the outer plexiform layer), outer retina (from the boundary between inner nuclear layer and the outer plexiform layer to the outer border of RPE layer), and SRF.

NCSME were non-center-involved) at baseline completed 6mo visit. Of 37 eyes in the Plus group and 22 eyes in the PRP group completed the study (21/37 with CSME in Plus group and 12/22 with CSME in PRP group, $P=0.276$). Totally 4 patients arranged for PPV were excluded as described in our published paper^[20]. There was no significant difference between the two comparison subgroups in demographic characteristics and basic ocular features (Table 1). Table 2 shows OCT parameters within a radius of 1500 μm centered in the OCT fovea. ICC of two HRD counts (by Sun BW and Zhao S) was 0.921.

Central Macula Thickness and Best Corrected Visual Acuity Changes There was no significant difference in CMT and BCVA between the two comparison subgroups at baseline (Figures 2A, 3A). Average CMT in the PRP group was significantly higher than in the Plus group at the end of the study (307.67 ± 61.89 vs 352 ± 77.75 , $P=0.019$), especially in patients with NCSME (269.88 ± 17.04 vs 321.44 ± 44.98 , $P=0.0002$; Figure 2B). After treatment CMT was significantly lower in the Plus group CSME patients, while the PRP group was significantly higher (Figure 2C-2E). At the end of the study, the average BCVA of Plus group was also greatly superior to PRP group (0.41 ± 0.17 vs 0.53 ± 0.19 , $P=0.01$), with BCVA in patients with CSME increased significantly in the Plus group (0.57 ± 0.12 vs 0.47 ± 0.17 , $P=0.03$; Figure 3B-3E).

Hyperreflective Dots Difference There were no significant differences in baseline layers of HRDs between the comparative subgroups (Figures 4A, 5A). The total number of HRDs in the Plus group was obviously lower than that in the PRP group after 6mo of treatment (10.56 ± 2.96 vs 17.18 ± 6.11 , $P<0.001$), mainly in the inner/outer retina layer ($P<0.001$, Figure 4B). Total HRDs decreased significantly in the Plus group after treatment (12.48 ± 3.76 vs 10.56 ± 2.96 , $P=0.017$), but increased significantly in PRP group (13.31 ± 5.58 vs 17.18 ± 6.11 , $P=0.035$; Figure 4C). As to HRDs at different retinal layers, IVC pre-treatment benefited on HRDs decreasing in the inner retina layer (7.89 ± 2.55 vs 5.45 ± 1.52 , $P<0.001$),

Table 1 Baseline characteristics

Parameters	Plus group (SD) n=37	PRP group (SD) n=22	P
Systemic			
Age (y)	53.36 (4.94)	52.39 (4.73)	0.603
Duration of DM (y)	12.72 (3.69)	13.95 (2.66)	0.384
HbA1c (%)	7.45 (0.24)	7.62(0.36)	0.433
Total cholesterol (mmol/L)	5.15 (1.39)	4.95 (1.44)	0.551
Triglycerides (mmol/L)	1.76 (0.24)	1.86 (0.21)	0.287
HDL cholesterol (mmol/L)	1.58 (0.71)	1.42 (0.65)	0.655
LDL cholesterol (mmol/L)	2.43 (0.87)	2.91 (0.73)	0.314
Ocular			
BCVA (logMAR)	0.47 (0.16)	0.49 (0.17)	0.731
IOP (mm Hg)	17.45 (1.51)	16.62 (1.81)	0.604
CMT (μm)	335 (61.37)	340.5 (61.29)	0.740
CSME (n)	21/33	12/33	0.745
NCSME (n)	16/26	10/26	0.781

DM: Diabetes mellitus; HDL: High density lipoprotein; LDL: Low density lipoprotein; BCVA: Best corrected visual acuity; IOP: Intraocular pressure; CMT: Central macula thickness.

Table 2 OCT manifestations in the macular area with a radius of 1500 μm centered on the fovea

Parameters	Plus group (n=37)		PRP group (n=22)	
	Baseline	Deadline	Baseline	Deadline
Sponge-like swelling	4	2	2	3
Cystoid macular edema	7	6	3	3
Neuroretinal detachment	0	0	0	0
Mixed type	12	11	7	9
Vitreomacular adhesion	2	3	1	1
DRIL	3	4	2	2
EZ disruption	5	5	2	3
ELM disruption	5	6	4	4

DRIL: Disorganization of retinal inner layers; EZ: Ellipsoid zone; EML: External limiting membrane.

while the PRP alone increased the HRDs in the outer retina layer (4.02 ± 1.97 vs 6.71 ± 2.41 , $P<0.001$; Figure 4D-4F). The similar benefits of combined treatment were shown in both groups with CSME or NCSME at baseline (Figure 5).

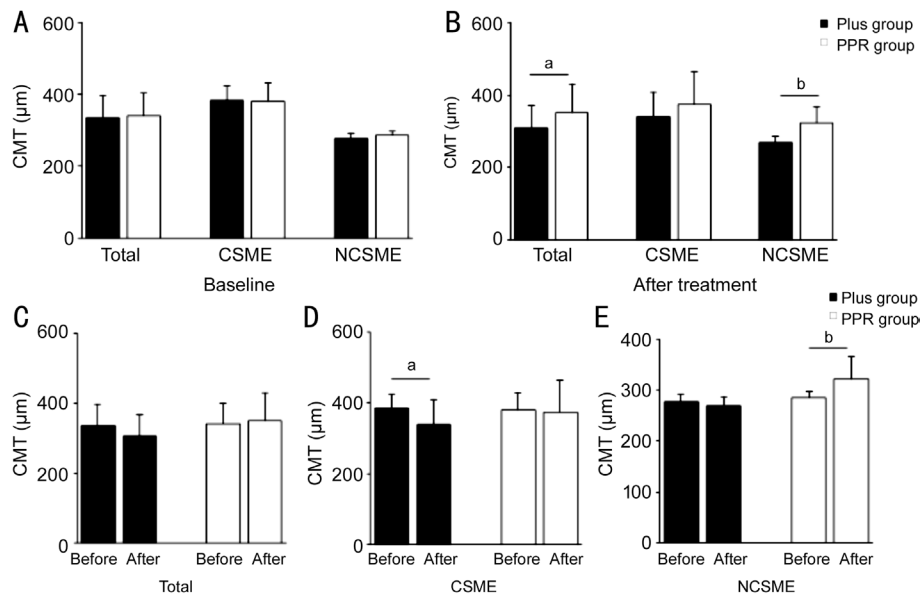


Figure 2 CMT changes A: The baseline CMT is well balanced in the two comparative subgroups; B: The average CMT in the PRP group was obviously higher than in the Plus group, especially in the NCSME patients after treatment; C: CMT was similar in both groups before and after treatment; D: CMT of CSME patients in the Plus group decreased significantly after treatment; E: CMT in NCSME patients after treatment increased significantly in the PRP group. ^a $P < 0.05$, ^b $P < 0.01$.

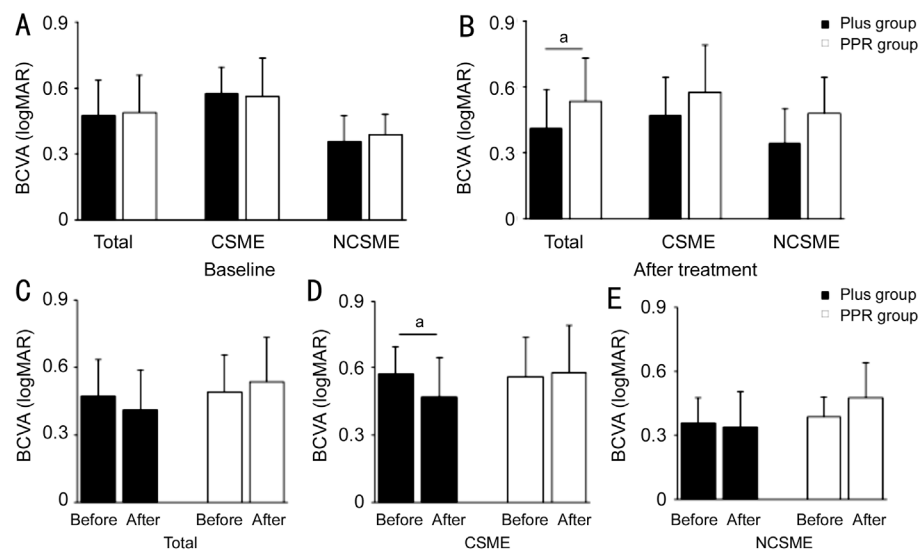


Figure 3 BCVA changes A: All the two comparative subgroups were well balanced overall for BCVA at baseline; B: The BCVA in the Plus group was significantly better than that in group PRP at the end of the experiment; C: The BCVA was similar in two groups before and after treatment; D: BCVA in CSME patients after treatment improved significantly in group Plus; E: The baseline and after treatment BCVA of NCSME patients in the two groups was similar. ^a $P < 0.05$.

DISCUSSION

The destruction of BRB and the increase of vascular permeability lead to the decompensation of RPE and the occurrence of DME. The presence of DME prior to PRP treatment can lead to an overburden of RPE, and PRP could be considered to exacerbation DME. Currently clinically, PDR patients with CSME are widely recommended to use anti-VEGF drugs combined with PRP^[21]. But, in eyes with NCSME at baseline, significant BCVA worsening and increased CMT was found in patients who received PRP treatment in

our study 3mo later^[20], in agree with previous studies^[22-23] and such phenomenon can be prevented by anti-VEGF pre-treatment^[20,24]. Anti-VEGF agents pre-treatment with PRP could also be recommended to PDR patient with NCSME at baseline.

The benefit of single dose conbercept pre-treatment, lasting more than 6mo in our present study, might not resulted from the pharmacological inhibition of conbercept because the average duration of DME between IVC treatments was 2.1mo^[25]. Breakdown of BRB was considered as risk factors

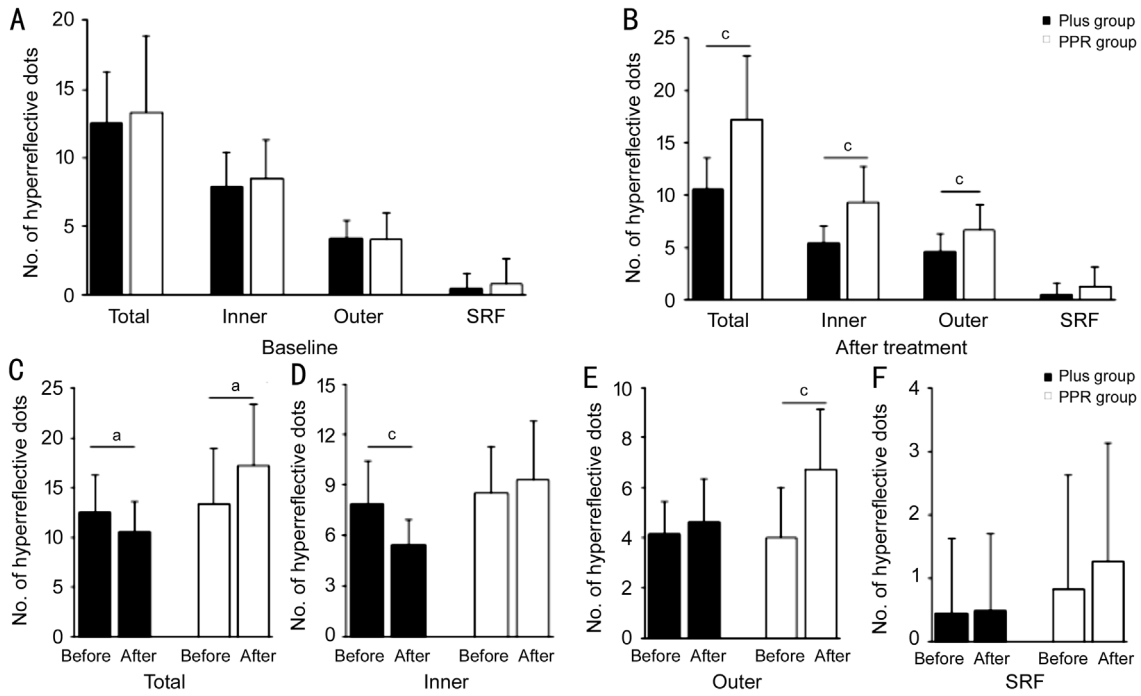


Figure 4 HRDs changes A: At baseline, the HRDs were similar in the two groups; B: The number of total HRDs was obviously lower in group Plus after 6mo of treatment than group PRP, especially in the inner retina layer; C: After treatment, the total HRDS in the plus group decreased significantly, but there was no significant change in the group with PRP; D: The amount of HRDs decreased in the inner retina layer in Plus group; E: The number of HRDs increased in the outer retina layer PRP group; F: No significant changes of the number of HRDs detected in SRF layer. ^a $P < 0.05$, ^c $P < 0.001$.

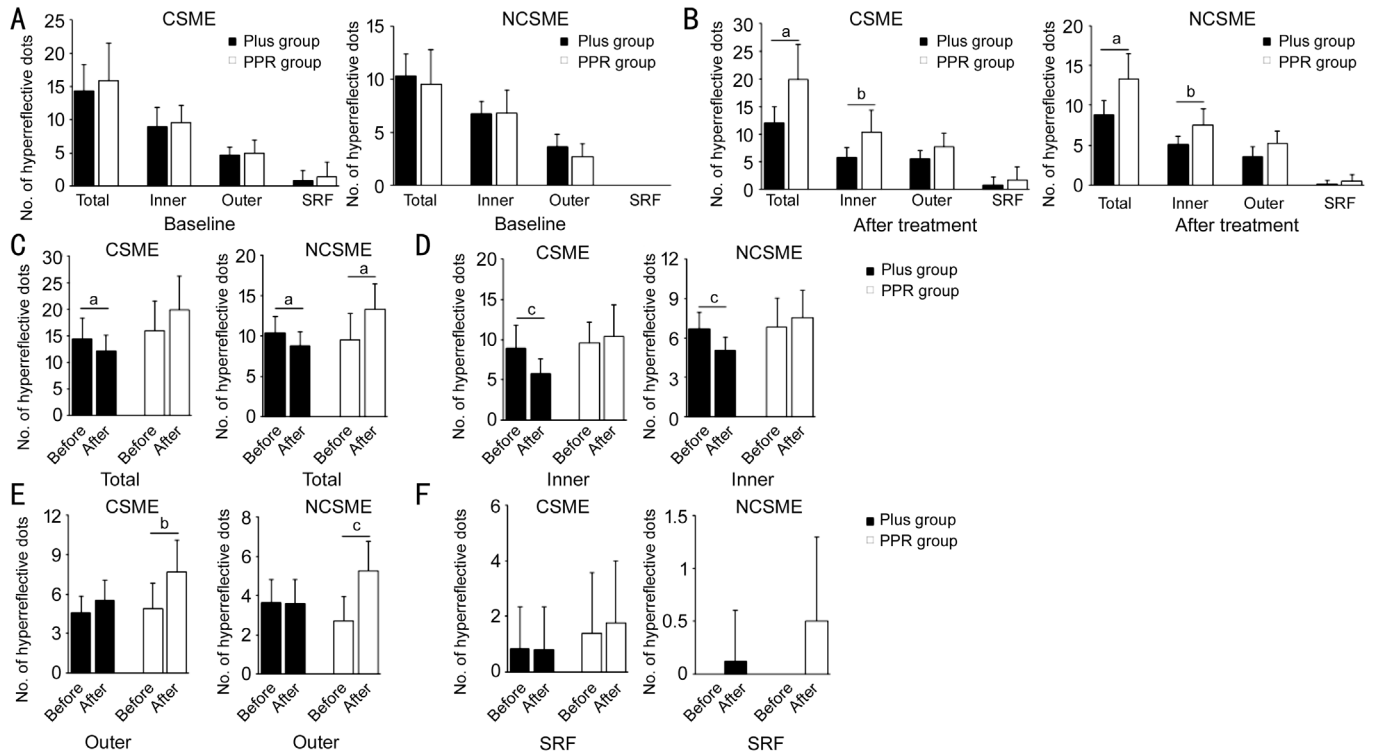


Figure 5 Similar HRDs changes in patients with CSME or NCSME A: The total HRDs between the comparison groups was similar at baseline; B: Of 6mo after treatment, the number of total HRDs was obviously higher in group PRP than group Plus, especially in the inner retina layer; C: After treatment, the total HRD decreased significantly in Plus group but not in PRP group; D: The number of HRDs decreased in the inner retina layer in Plus group; E: The number of HRDs increased in the outer retina layer PRP group; F: No significant changes of the number of HRDs detected in SRF layer. ^a $P < 0.05$, ^b $P < 0.01$, ^c $P < 0.001$.

for progression of DR and DME^[11]. We speculated that the stabilization of BRB with anti-VEGF agents pre-treatment before PRP could be responsible for better BCVA and less CMT in longer period.

Besides increased DME and VH, HEs deposition is another frequent complication after PRP treatment in PDR. The serous infiltration of injured capillaries increased, then inflammatory responses with lipid-laden macrophages followed, ultimately developed into HEs^[16,26]. DME combined with HEs has multiple treatments, including intravitreal steroid injection. (triamcinolone acetonide, Dongkwang, Seoul, Korea; dexamethasone implant, Allergan Inc., Irvine, CA, USA; 700 µg), and anti-VEGF agents (such as bevacizumab, Genentech Inc., South San Francisco, CA, USA; ranibizumab, Genentech, San Francisco, CA, USA). Intravitreal steroids significantly reduced HEs in patients with DME after 3mo, while intravitreal bevacizumab remained unchanged obviously^[27]. Although an ex post facto study of the BEVORDEX trial indicated that intravitreal bevacizumab injection also significantly decrease HEs, but it was required every four weeks and for up to 12mo^[28]. Compared with anti-VEGF agents, the mechanism of the different effects of steroid on HEs could be additional functions of anti-inflammatory, vasoconstrictive effects and antipermeability effects. These might lead to the faster reduction of HE in the steroid treatment group. But there are still a lot of HEs on the macular which are still very difficult to remove^[27]. So preventing HEs formation would be a better choice in clinic.

HRDs in SD-OCT are the morphologic manifestations of a very early subclinical features when lipid extravasation after inner BRB rupture in DR^[29]. Other studies have shown that HRDs have linked to inflammation of the retina. Vujosevic *et al*^[30] reported HRDs were mainly located in the inner retina in the early phase of DR, where resident microglia existed. HRDs gradually reaches the outer layer of the retina as the retinopathy progresses^[30-31]. Therefore, the increased amount of HRDs in SD-OCT might symbolized lipoprotein extravasation after breakdown of the inner BRB and an activated inflammatory process in the retina. In our present study, PRP alone increased the total amount of HRDs at baseline, especially in patients who did not have CSME. However, IVC pretreatment before PRP can effectively inhibit the formation of HRDs. PRP in PDR deteriorated the BRB shortly after the initial laser treatment^[32], which will lead to extravasation of fluid and macromolecules such as plasma lipids and proteins. The inflammation induced after breakdown of BRB accelerated the progress of DME with HE^[12-13]. Although anti-VEGF agents did not work well in clearing HEs because shortage of anti-inflammatory and vasoconstrictive effects, it could strongly stabilize BRB^[27]. That could be the

possible mechanism of one dose IVC pretreatment before PRP decreasing HDRs formation effectively in our study. Another reason could be that SD-OCT is much more sensitive to detect the change of HRDs than calculating the changes of area or pixels of HEs on fundus photos as used in previous studies, which is helpful to study the physiological characteristics of diabetic retina and its therapeutic effect.

In this study, we detected HRDs in SD-OCT in all retina layers. In PRP group, significant HRDs increased in outer layer of the retina, which may be explained by the theory that the activated microglia migration from inner to outer layer. Another possible mechanism could be the dynamic changes of hyperreflective foci. HE will increase in the anti-VEGF treatment of DME due to the accumulation of micro-exudate caused by rapid thinning of the retina^[17]. Whether such side effect of anti-VEGF therapy is detrimental to anatomical rehabilitation, such as diabetic macular degeneration with the tendency of HEs accumulating in the fovea is unclear.

In this study, we also detected that IVC pre-treatment inhibited HRDs increasing in outer retina and even decreased HRDs in inner retina. The HRDs in outer layers composed with more inflammatory lipid-filled macrophages, are not easy to be cleared by anti-VEGF agents lacking anti-inflammatory and vasoconstrictive effects. But the decrease of HRDs in inner could benefit from stabilization of BRB by anti-VEGF agents. In addition, the optimal time for pretreatment was observed to be 1wk before PRP with intravitreal injection of anti-VEGF agents. In this way, the antiproliferative effects of anti-VEGF agents could maximum the function of reducing the laser energy required for PRP. It could also stabilize BRB and reduce lipid exudates in the macular region during PRP. The limitation of our study was the need for larger sample sizes and follow-up times to help validate and confirm the study results. Also consider the deviation cause by the exclusion or withdrawal of 35 of the 94 patients at the end of 6mo. It has been suggested in the literature that hyperlipidemia in diabetic patients may lead to the occurrence and development of retinal HEs and CSME^[33]. Although the average lipids levels were well balanced in the two groups at start, we did not follow the changes of lipids levels during the study. The high resolution of SD-OCT is enough for the eye tracking system to compare the same retinal position in each follow-up tests. But we also need to consider that DME changes would also results in lateral changes in the structure of the retina, thereby individual HRDs may be missed in subsequent scans.

To sum up, we can conclude that the treatment of IVE in PDR is an effective PRP adjuvant therapy regardless of baseline CEME. Single dose IVC pretreatment before PRP could help stable the BRB during PRP and effectively reduce the lipid exudates and inhibit the formation of early hard exudates in PDR.

ACKNOWLEDGEMENTS

We thank Dr. Bo-Wen Sun and Shuan Zhao for HRD counts.

Conflicts of Interest: Shi JR, None; Zhang Q, None; Zhang T, None; Zhuang H, None; Sun ZC, None; Qin YW, None.

REFERENCES

- 1 Otani T, Kishi S. Tomographic findings of foveal hard exudates in diabetic macular edema. *Am J Ophthalmol* 2001;131(1):50-54.
- 2 Larsson J, Kifley A, Zhu M, Wang JJ, Mitchell P, Sutter FK, Gillies MC. Rapid reduction of hard exudates in eyes with diabetic retinopathy after intravitreal triamcinolone: data from a randomized, placebo-controlled, clinical trial. *Acta Ophthalmol* 2009;87(3):275-280.
- 3 Early photocoagulation for diabetic retinopathy. ETDRS report number 9. Early Treatment Diabetic Retinopathy Study Research Group. *Ophthalmology* 1991;98(5):766-785.
- 4 Figueira J, Silva R, Henriques J, Caldeira Rosa P, Laíns I, Melo P, Gonçalves Nunes S, Cunha-Vaz J. Ranibizumab for high-risk proliferative diabetic retinopathy: an exploratory randomized controlled trial. *Ophthalmologica* 2016;235(1):34-41.
- 5 Yang CS, Hung KC, Huang YM, Hsu WM. Intravitreal bevacizumab (Avastin) and panretinal photocoagulation in the treatment of high-risk proliferative diabetic retinopathy. *J Ocul Pharmacol Ther* 2013;29(6):550-555.
- 6 Chew EY, Klein ML, Ferris FL 3rd, Remaley NA, Murphy RP, Chantry K, Hoogwerf BJ, Miller D. Association of elevated serum lipid levels with retinal hard exudate in diabetic retinopathy. Early Treatment Diabetic Retinopathy Study (ETDRS) Report 22. *Arch Ophthalmol* 1996;114(9):1079-1084.
- 7 Yamaguchi M, Nakao S, Kaizu Y, Kobayashi Y, Nakama T, Arima M, Yoshida S, Oshima Y, Takeda A, Ikeda Y, Mukai S, Ishibashi T, Sonoda KH. High-resolution imaging by adaptive optics scanning laser ophthalmoscopy reveals two morphologically distinct types of retinal hard exudates. *Sci Rep* 2016;6:33574.
- 8 Cusick M, Chew EY, Chan CC, Kruth HS, Murphy RP, Ferris FL 3rd. Histopathology and regression of retinal hard exudates in diabetic retinopathy after reduction of elevated serum lipid levels. *Ophthalmology* 2003;110(11):2126-2133.
- 9 Sander B, Larsen M, Engler C, Lund-Andersen H, Parving HH. Early changes in diabetic retinopathy: capillary loss and blood-retina barrier permeability in relation to metabolic control. *Acta Ophthalmol (Copenh)* 1994;72(5):553-559.
- 10 Cunha-Vaz JG. Studies on the pathophysiology of diabetic retinopathy. The blood-retinal barrier in diabetes. *Diabetes* 1983;32(Suppl 2):20-27.
- 11 Sander B, Hamann P, Larsen M. A 5-year follow-up of photocoagulation in diabetic macular edema: the prognostic value of vascular leakage for visual loss. *Graefes Arch Clin Exp Ophthalmol* 2008;246(11):1535-1539.
- 12 Zweig K, Cunha-Vaz J, Peyman G, Stein M, Raichand M. Effect of argon laser photocoagulation on fluorescein transport across the blood-retinal barrier. *Exp Eye Res* 1981;32(3):323-329.
- 13 Arrindell EL, Wu JC, Wolf MD, Nanda S, Han DP, Wong EC, Abrams GW, Mieler WF, Hyde JS. High-resolution magnetic resonance imaging evaluation of blood-retinal barrier integrity following transscleral diode laser treatment. *Arch Ophthalmol* 1995;113(1):96-102.
- 14 Murata T, Nakagawa K, Khalil A, Ishibashi T, Inomata H, Sueishi K. The relation between expression of vascular endothelial growth factor and breakdown of the blood-retinal barrier in diabetic rat retinas. *Lab Invest* 1996;74(4):819-825.
- 15 Pe'er J, Folberg R, Itin A, Gnessin H, Hemo I, Keshet E. Upregulated expression of vascular endothelial growth factor in proliferative diabetic retinopathy. *Br J Ophthalmol* 1996;80(3):241-245.
- 16 Chen MS, Chang CC, Lin CP, Wang PC, Lin LR, Hou PK, Ho TC. Role of vascular endothelial growth factor in the breakdown of the blood-aqueous barrier after retinal laser photocoagulation in pigmented rabbits. *J Ocul Pharmacol Ther* 2012;28(1):83-88.
- 17 Pemp B, Deák G, Prager S, Mitsch C, Lammer J, Schmidinger G, Scholda C, Schmidt-Erfurth U, Bolz M; Diabetic Retinopathy Research Group Vienna. Distribution of intraretinal exudates in diabetic macular edema during anti-vascular endothelial growth factor therapy observed by spectral domain optical coherence tomography and fundus photography. *Retina* 2014;34(12):2407-2415.
- 18 Hwang HS, Chae JB, Kim JY, Kim DY. Association between hyperreflective dots on spectral-domain optical coherence tomography in macular edema and response to treatment. *Invest Ophthalmol Vis Sci* 2017;58(13):5958-5967.
- 19 Kang JW, Chung H, Chan Kim H. Correlation of optical coherence tomographic hyperreflective foci with visual outcomes in different patterns of diabetic macular edema. *Retina* 2016;36(9):1630-1639.
- 20 Zhang Q, Zhang T, Zhuang H, Sun ZC, Qin YW. Single-dose intravitreal conbercept before panretinal photocoagulation as an effective adjunctive treatment in Chinese proliferative diabetic retinopathy. *Ophthalmologica* 2019;242(2):59-68.
- 21 Figueira J, Fletcher E, Massin P, et al. Ranibizumab plus panretinal photocoagulation versus panretinal photocoagulation alone for high-risk proliferative diabetic retinopathy (PROTEUS study). *Ophthalmology* 2018;125(5):691-700.
- 22 McDonald HR, Schatz H. Macular edema following panretinal photocoagulation. *Retina* 1985;5(1):5-10.
- 23 Higgins KE, Meyers SM, Jaffe MJ, Roy MS, de Monasterio FM. Temporary loss of foveal contrast sensitivity associated with panretinal photocoagulation. *Arch Ophthalmol* 1986;104(7):997-1003.
- 24 Cho WB, Moon JW, Kim HC. Intravitreal triamcinolone and bevacizumab as adjunctive treatments to panretinal photocoagulation in diabetic retinopathy. *Br J Ophthalmol* 2010;94(7):858-863.
- 25 Xu Y, Rong A, Bi Y, Xu W. Intravitreal conbercept injection with and without grid laser photocoagulation in the treatment of diffuse diabetic macular edema in real-life clinical practice. *J Ophthalmol* 2016;2016:2143082.

- 26 Marupally AG, Vupparaboina KK, Peguda HK, Richhariya A, Jana S, Chhablani J. Semi-automated quantification of hard exudates in colour fundus photographs diagnosed with diabetic retinopathy. *BMC Ophthalmol* 2017;17(1):172.
- 27 Shin YU, Hong EH, Lim HW, Kang MH, Seong M, Cho H. Quantitative evaluation of hard exudates in diabetic macular edema after short-term intravitreal triamcinolone, dexamethasone implant or bevacizumab injections. *BMC Ophthalmol* 2017;17(1):182.
- 28 Mehta H, Fraser-Bell S, Yeung A, *et al.* Efficacy of dexamethasone versus bevacizumab on regression of hard exudates in diabetic maculopathy: data from the BEVORDEX randomised clinical trial. *Br J Ophthalmol* 2016;100(7):1000-1004.
- 29 Bolz M, Schmidt-Erfurth U, Deak G, Mylonas G, Kriechbaum K, Scholda C; Diabetic Retinopathy Research Group Vienna. Optical coherence tomographic hyperreflective foci: a morphologic sign of lipid extravasation in diabetic macular edema. *Ophthalmology* 2009;116(5):914-920.
- 30 Vujosevic S, Bini S, Midena G, Berton M, Pilotto E, Midena E. Hyperreflective intraretinal spots in diabetics without and with nonproliferative diabetic retinopathy: an *in vivo* study using spectral domain OCT. *J Diabetes Res* 2013;2013:491835.
- 31 Zeng HY, Green WR, Tso MO. Microglial activation in human diabetic retinopathy. *Arch Ophthalmol* 2008;126(2):227-232.
- 32 Larsson LI, Nuija E. Increased permeability of the blood-aqueous barrier after panretinal photocoagulation for proliferative diabetic retinopathy. *Acta Ophthalmol Scand* 2001;79(4):414-416.
- 33 Sasaki M, Kawasaki R, Noonan JE, Wong TY, Lamoureux E, Wang JJ. Quantitative measurement of hard exudates in patients with diabetes and their associations with serum lipid levels. *Invest Ophthalmol Vis Sci* 2013;54(8):5544-5550.