

# Bietti's crystalline dystrophy in an African American patient: an unusual racial demographic for a condition more common in individuals of East Asian descent

Virang Kumar<sup>1</sup>, Vikram Brar<sup>2</sup>, Jordyn Prell<sup>3</sup>, Ann Jewell<sup>3</sup>, Natario Couser<sup>2,3,4</sup>

<sup>1</sup>Virginia Commonwealth University School of Medicine, Richmond, VA 23298, USA

<sup>2</sup>Department of Ophthalmology, Virginia Commonwealth University School of Medicine, Richmond, VA 23298, USA

<sup>3</sup>Department of Human and Molecular Genetics, Virginia Commonwealth University School of Medicine, Richmond, VA 23298, USA

<sup>4</sup>Department of Pediatrics, Virginia Commonwealth University School of Medicine, Richmond, VA 23298, USA

**Correspondence to:** Natario Couser. Department of Ophthalmology, Virginia Commonwealth University School of Medicine, Richmond, VA 23298, USA. natario.couser@vcuhealth.org

Received: 2020-04-26 Accepted: 2021-01-20

**DOI:10.18240/ijo.2021.08.24**

**Citation:** Kumar V, Brar V, Prell J, Jewell A, Couser N. Bietti's crystalline dystrophy in an African American patient: an unusual racial demographic for a condition more common in individuals of East Asian descent. *Int J Ophthalmol* 2021;14(8):1291-1292

**Dear Editor,**

The study outlining the manifestations of Bietti's crystalline dystrophy (BCD) in five Chinese patients offered insights into common disease-causing variants associated with Chinese patients as well as a novel mutation<sup>[1]</sup>. This genetic condition is commonly reported among East Asian populations and to some extent Mediterranean populations<sup>[2]</sup>. The purpose of this letter is to report the clinical and recently obtained molecular genetic testing characteristics in a patient who is African American, a racial demographic not typically associated with this disease.

A 76-year-old African American female previously reported with BCD based on her clinical presentation, underwent genetic testing for molecular confirmation in July 2019; this report details the molecular testing results<sup>[3]</sup>. She had an inherited retinal dystrophies gene sequencing and deletion/duplication panel performed which included 248 genes. This testing revealed a pathogenic variant and a variant of uncertain

significance in *CYP4V2*, the gene associated with autosomal recessive BCD.

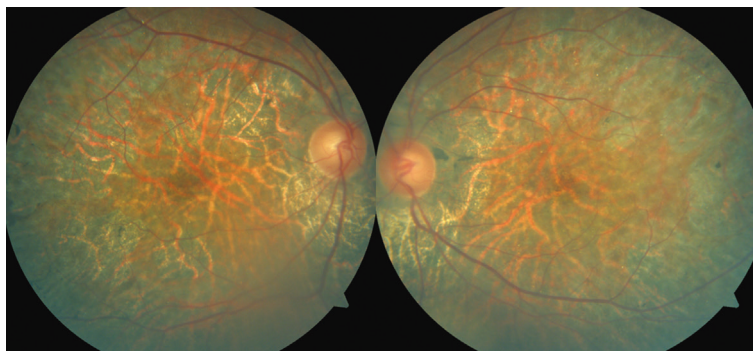
The testing also showed mutations in three other genes: *CEP41*: c.431G>A (p.Ser144Asn), *IFT172*: c.2158C>T (p.Arg720Cys), and *RBP3*: c.1400C>T (p.Pro467Leu); all of these were classified as variants of uncertain significance. None of these three variants are suspected to be a part of BCD nor relevant for this patient's clinical phenotype.

The first variant in *CYP4V2* is a heterozygous deletion encompassing exon 1, including the initiator codon, which is classified as pathogenic. This variant is expected to result in an absent or disrupted protein product and has not been previously reported in the literature. However, variants that result in loss of function in *CYP4V2* are known to be pathogenic; thus, this variant has been classified as such<sup>[4-5]</sup>.

The other variant identified is a heterozygous missense variant, *CYP4V2* c.1523G>A (p.Arg508His), classified as a variant of uncertain significance. This change results in a substitution of arginine for histidine at codon 508 of the *CYP4V2* protein. The arginine residue in this position is highly conserved and there is a small physiochemical difference between arginine and histidine. This variant is present in population databases (rs119103284, ExAC 0.01%) and prediction algorithm results for this change are either unavailable or do not agree on the potential impact. Additionally, this variant has been observed in individuals affected with clinical features of BCD and is possibly predicted to have a functional impact on the protein<sup>[4]</sup>. It has been reported in ClinVar as pathogenic for this study<sup>[6]</sup>. Given the conflicting evidence, this missense variant was classified as a variant of uncertain significance.

Of note, the test could not determine if the *CYP4V2* variants are in *cis* or *trans*. Additional informative relatives were not available for testing at this time. Based on her clinical presentation, it is most likely that both mutations identified are disease causing and one is on each copy of the gene.

The c.1523G>A variant has been reported in a patient of European descent, possibly suggesting our reported patient may have European heritage, or that the patient of European descent may have African heritage, although more patients of both populations would be required to understand this



**Figure 1** Fundoscopic exam showing bilateral presence of yellow-white retinal deposits and RPE atrophy in the mid-peripheral fundus.

relationship<sup>[2,4]</sup>. This differs from common mutations in Chinese patients, which includes the c.802-8\_810del17insGC and c.1091-21>G mutations, as well as c.992A>C<sup>[1-2]</sup>.

Upon her last ophthalmic examination, her best corrected visual acuities were 20/30-2 and 20/25-1. There was no evidence of corneal deposits on slit-lamp evaluation of the anterior segment. Dilated fundus examination was stable in comparison to previous exams, with numerous yellow-white retinal deposits and multifocal areas of retinal pigment epithelium (RPE) atrophy in the mid-peripheral fundus of both eyes (Figure 1).

Likewise, in the Chinese patients, corneal crystals were absent, while RPE atrophy and yellow crystals in the fundi were present in all five patients. This pattern of findings, referred to as a pure retinal form, has been shown to be more common among Asian populations rather than Caucasian populations<sup>[1]</sup>. Thus, more data on the phenotypes of African American patients with BCD could further elucidate the presence or absence of this pattern.

In conclusion, this letter compares the presentation of BCD in a patient from a rarer population to those of a commonly studied population. Such a comparison can be useful when distinguishing different genotypic and phenotypic patterns among different populations, especially as more cases are reported. Ultimately, such efforts can allow for more targeted and individualized therapies to be developed.

#### ACKNOWLEDGEMENTS

**Conflicts of Interest:** Kumar V, None; Brar V, None; Prell J, None; Jewell A, None; Couser N, 1) Principal Investigator for Retrophin at the VCU site, 2) Book editor for Elsevier.

#### REFERENCES

- 1 Tian R, Wang SR, Wang J, Chen YX. Novel CYP4V2 mutations associated with Bietti crystalline corneoretinal dystrophy in Chinese patients. *Int J Ophthalmol* 2015;8(3):465-469.
- 2 García-García GP, Martínez-Rubio M, Moya-Moya MA, Pérez-Santonja JJ, Escibano J. Current perspectives in Bietti crystalline dystrophy. *Clin Ophthalmol* 2019;13:1379-1399.
- 3 Brar VS, Benson WH. Infrared imaging enhances retinal crystals in Bietti's crystalline dystrophy. *Clin Ophthalmol* 2015;9:645-648.
- 4 Li A, Jiao X, Munier FL, Schorderet DF, Yao W, Iwata F, Hayakawa M, Kanai A, Shy Chen M, Alan Lewis R, Heckenlively J, Weleber RG, Traboulsi EI, Zhang Q, Xiao X, Kaiser-Kupfer M, Sergeev YV, Hejtmancik JF. Bietti crystalline corneoretinal dystrophy is caused by mutations in the novel gene CYP4V2. *Am J Hum Genet* 2004;74(5):817-826.
- 5 Lockhart CM, Nakano M, Rettie AE, Kelly EJ. Generation and characterization of a murine model of Bietti crystalline dystrophy. *Invest Ophthalmol Vis Sci* 2014;55(9):5572-5581.
- 6 National Center for Biotechnology Information. ClinVar; [VCV000002189.1]. <https://www.ncbi.nlm.nih.gov/clinvar/variation/VCV000002189.1>. Accessed on April 21, 2020.