

Exogenous testosterone therapy on choroid in androgen deficiency

Volkan Yeter¹, Nurullah Koçak¹, Merve Kalyoncu¹, Ramazan Aşçı², Nurşen Aritürk¹

¹Department of Ophthalmology, Ondokuz Mayıs University, Samsun 55139, Turkey

²Department of Urology, Ondokuz Mayıs University, Samsun 55139, Turkey

Correspondence to: Volkan Yeter. Department of Ophthalmology, Ondokuz Mayıs University, Samsun 55139, Turkey. dr.volkanyeter@gmail.com

Received: 2023-05-23 Accepted: 2024-04-23

Abstract

AIM: To investigate the effects of exogenous testosterone treatment on the choroidal parameters in patients with androgen deficiency.

METHODS: Right eyes of 24 patients with androgen deficiency and 31 healthy volunteers were included in the study. The eyes were scanned for subfoveal choroidal thickness (SFCT), choroidal vascularity index (CVI), choroid-stromal area (C-SA), choroid-luminal area (C-LA), choroid-stromal to luminal area ratio (CSLR), and the choroidal parameters within central 1500 µm of the macula (CVI₁₅₀₀, C-LA₁₅₀₀, C-SA₁₅₀₀, and CSLR₁₅₀₀) by enhanced-depth imaging optical coherence tomography (EDI-OCT) at baseline, 6th and 18th weeks of the exogenous testosterone treatment.

RESULTS: The mean SFCT values of the androgen deficient groups and healthy controls were 307.7±27.0 and 303.2±37.2 µm ($P=0.8$). However, CVI, C-SA, CSLR, CVI₁₅₀₀, C-LA₁₅₀₀, and CSLR₁₅₀₀ were significantly different between the groups (all $P<0.01$). At the 6th week visit after exogenous testosterone treatment, SFCT, CVI, C-LA, and C-SA were significantly decreased, and these parameters returned to baseline levels at the 18th-week visit (all $P>0.05$). However, CVI₁₅₀₀ and LA₁₅₀₀ significantly increased at the end of the follow-up period ($P<0.001$).

• **CONCLUSION:** CVI is lower in androgen-deficient patients than in healthy subjects. The alterations in the choroid during the testosterone peak are transient in the treatment of patients with androgen deficiency. However, the increase in CVI within the central 1500 µm of the macula persists even after 4mo.

• **KEYWORDS:** testosterone; androgen deficiency; choroid; vascularity index

DOI:10.18240/ijo.2024.08.15

Citation: Yeter V, Koçak N, Kalyoncu M, Aşçı R, Aritürk N. Exogenous testosterone therapy on choroid in androgen deficiency. *Int J Ophthalmol* 2024;17(8):1489-1494

INTRODUCTION

Exogenous testosterone is an approved treatment for androgen deficiency in men and it may be also used for fatigue, osteopenia, depression, cognitive decline, and low libido in clinical practice^[1-5]. Previously, it was shown that exogenous testosterone use may cause central serous chorioretinopathy (CSC) in men and women^[1-5], and clinical evidence supports the possible role of testosterone in the pathogenesis of CSC^[6].

CSC is more common in men than women, and the incidence of CSC decreases after age 45 in men due to a decline in plasma androgen levels^[7]. Elevated plasma levels of testosterone are associated with Type A personality, and psychologic stress^[8]. Çiloğlu *et al*^[6] recently found that serum testosterone levels were higher in the patients with CSC than in age- and sex-matched healthy controls while there was no difference in serum cortisol levels between the groups. It was shown that testosterone level is associated with ocular blood velocity and vascular resistance^[9]. In addition, the choroid and retinal pigment epithelium have testosterone receptors as many ocular structures^[10], and the anti-androgenic agent, finasteride, has been found to be an effective treatment for CSC^[11].

Although there are many reports presenting evidence about the role of testosterone in some clinical presentations related to choroidal pathophysiology, there is no study comparing the choroidal parameters in androgen-deficient subjects with those in healthy subjects, and investigating the changes in choroidal parameters by exogenous testosterone to show direct effects of testosterone on the choroid with androgen deficiency.

In choroidal evaluation, the most commonly used parameter is choroidal thickness. However, many factors including axial length, intraocular pressure (IOP), and systemic blood pressure may have some influences on the choroidal thickness, and it may fluctuate throughout the day^[12]. Recently, the choroidal vascularity index (CVI) was reported as a novel quantitative

choroidal imaging parameter, which shows resistance to the effects of these factors and is more consistent than the choroidal thickness during the day^[12]. Choroidal-stromal (C-SA) and -luminal vascular (C-LA) areas can be differentiated and quantified by this image-binarization method, and the changes in vascular and stromal components of the choroid can be effectively detected. These choroidal parameters have been previously studied in various systemic and retinal diseases^[12].

The main purpose of the present study is to investigate the alterations in the choroidal parameters due to exogenous testosterone treatment in patients with androgen deficiency. We also aimed to compare the choroidal parameters between androgen-deficient patients and healthy subjects with normal serum testosterone levels to show the effects of androgen deficiency on the choroid.

SUBJECTS AND METHODS

Ethical Approval The present study was approved by the Human Research Ethics Committee of Ondokuz Mayıs University (Approval No.OMU KAEK 2021/557). Informed consent was obtained from the patients for the use of their data. It was conducted in accordance with the tenets of the Declaration of Helsinki.

Subjects In this study, the data of the participants included in the previous study investigating the effects of the change in the androgen level on the ocular surface conducted in the Department of Ophthalmology, Ondokuz Mayıs University between January 2019 and January 2020 were retrospectively analyzed.

The patients, who had complaints of myalgia, excessive tearing, decrease in muscle strength, low libido, and erectile dysfunction with serum androgen levels below 231 ng/dL, were diagnosed with androgen deficiency in the Department of Urology, Ondokuz Mayıs University. The androgen-deficient patients applied to the Department of Ophthalmology, Ondokuz Mayıs University for comprehensive ophthalmologic examination and the ocular surface evaluation at baseline, 6th and 18th weeks of exogenous testosterone therapy. The control subjects were recruited from healthy male volunteers who applied for the annual ophthalmologic examination. All controls were measured for serum testosterone levels and the serum testosterone level >346 ng/dL was considered normal^[13].

Thirty-seven patients with androgen deficiency and 40 healthy controls in the previous study were retrospectively evaluated. The participants, who had been routinely examined by optical coherence tomography (OCT) for chorioretinal pathology after comprehensive ophthalmologic examination at baseline and every visit, were investigated. Exclusion criteria included the presence of any ocular disease; smoking; history of ocular surgery; use of any topical medicine; systemic diseases except hypertension; myopia \leq -3 D or hypermetropia \geq +3 D; having

no or unreliable OCT imaging for choroidal measurements at baseline or follow-up visits.

The patients with androgen deficiency were treated with intramuscular testosterone injections (Sustanon 250 mg/mL injectable solution, Ever Pharma Jena GmbH, Jena, Germany) every 2wk. Each injection contained 30 mg testosterone propionate, 60 mg testosterone phenylpropionate, 60 mg testosterone isocaproate, and 100 mg testosterone decanoate. These 4 compounds are the esters of the testosterone hormone. After the baseline examination, hormone replacement treatment was started. The control visits were performed in the 6th week, 5d after the 4th injection, and in the 18th week, 5d after the 10th injection. Serum testosterone levels of the patients were measured at each visit, and the blood samples were routinely taken between 08:00 *a.m.* and 12:00 *a.m.* There was not any alteration in systemic drug regimens of the androgen-deficient patients during the follow-up period.

The right eyes, which had enhanced-depth (EDI) scans previously obtained by spectral domain-OCT (SD-OCT) (Spectralis, Heidelberg Engineering, Heidelberg, Germany) for the evaluation of any chorioretinal abnormalities at baseline and follow-up visits, were retrospectively evaluated for the choroidal measurements. Twenty-four androgen-deficient patients had complete OCT scans obtained at the baseline and follow-up visits and 37 healthy controls had reliable OCT scans at the baseline. After matching for age, 6 healthy subjects were extracted from the control group. Thus, 24 patients with androgen deficiency and 31 healthy subjects were included in the study.

Choroidal Measurements All the measurements had been performed at the same time interval between 09:00 *a.m.* and 12:00 *a.m.* by a masked technician. The horizontal 6 mm-line scan centered on the fovea was used to measure the choroidal parameters. The subfoveal choroidal thickness (SFCT) was measured with the software tool of the OCT device. SFCT was determined by measuring the vertical distance between the outer surface of the retinal pigment epithelium and the choroidal-sclera interface. The image of the EDI-OCT scan, which was used to obtain SFCT, was exported to the software, Image J (version 1.52a, by the National Institutes of Health, Bethesda, MD, USA; <http://imagej.nih.gov/ij/>), for image binarization as previously reported^[14]. The total choroidal area and the areas of dark (C-LA) and light (C-SA) pixels were calculated after the image binarization (Figure 1A). CVI was determined by dividing C-LA by the total choroidal area. The proportion of C-SA to C-LA was defined as choroid-stromal to luminal area ratio (CSLR). In the study, the parameters of CVI, C-LA, C-SA, and CSLR for the area of central fovea within 1500 μ m were defined as CVI₁₅₀₀, C-LA₁₅₀₀, C-SA₁₅₀₀, and CSLR₁₅₀₀, respectively (Figure 1B). The choroidal parameters

Table 1 The characteristics of androgen deficient and control groups mean±SD (range)

Parameters	Androgen deficient group (n=24)	Healthy controls (n=31)	P
Age, y	59.67±8.18 (45 to 77)	60.74±6.34 (48 to 73)	0.6
Spherical equivalent, D	-0.01±2.37 (-2.75 to 2.75)	0.32±1.1 (-2.75 to 2.00)	0.5
Intraocular pressure, mm Hg	14.38±2.6 (10 to 18)	14.03±2.5 (9 to 18)	0.6
Hypertension, n (%)	9 (37.5)	12 (38.7)	0.1
Serum testosterone level, ng/dL	205.0±28.9 (95 to 231)	526.7±102.1 (348 to 720)	<0.00001 ^a

^aP<0.05 indicated statistical significance.

Table 2 Comparison of the choroidal parameters between the patients with androgen deficiency and healthy controls mean±SD (range)

Parameters	Androgen deficient group (n=24)	Healthy controls (n=31)	P
SFCT (μm)	307.7±27.0 (263–371)	303.2±37.2 (220–371)	0.8
CVI	0.62±0.05 (0.51–0.71)	0.67±0.06 (0.59–0.92)	0.002 ^a
C-SA (mm ²)	279.6±60.8 (178–411)	224.7±67.9 (64–345)	0.006 ^a
C-LA (mm ²)	449.9±75.8 (299–588)	454.4±112.1 (275–756)	0.7
CSLR	0.63±0.13 (0.42–0.98)	0.51±0.12 (0.1–0.68)	0.002 ^a
CVI ₁₅₀₀	0.63±0.04 (0.53–0.70)	0.68±0.04 (0.61–0.77)	0.001 ^a
C-SA ₁₅₀₀ (mm ²)	64.3±10.7 (49–78)	72.0±42.4 (45–255)	0.7
C-LA ₁₅₀₀ (mm ²)	111.3±12.6 (86–132)	127.2±13.6 (108–172)	0.0001 ^a
CSLR ₁₅₀₀	0.59±0.12 (0.42–0.89)	0.48±0.09 (0.30–0.64)	0.001 ^a

C-LA: Luminal area of choroid; C-SA: Stromal area of choroid; CSLR: Choroid-stromal to luminal area ratio (the ratio of C-SA/C-LA); CVI: Choroidal vascularity index; SFCT: Subfoveal choroidal thickness; CVI₁₅₀₀, C-SA₁₅₀₀, C-LA₁₅₀₀, and CSLR₁₅₀₀: CVI, C-SA, C-LA, and CSLR within 1500 μm of central fovea, respectively. ^aP<0.05 indicated statistical significance.

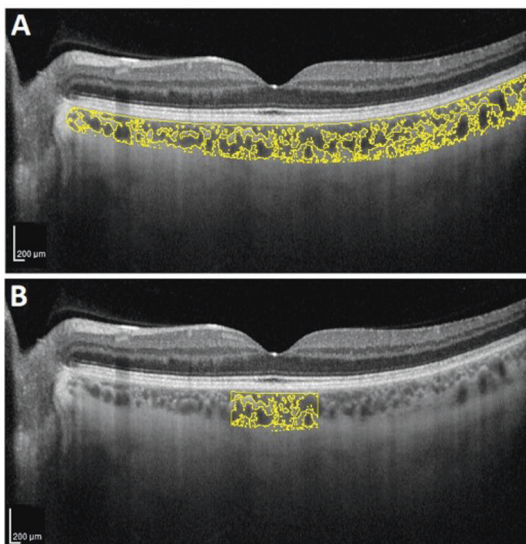


Figure 1 Image binarizations of the total choroidal area (A) and the subfoveal choroidal area within the central 1500 μm (B) are shown in the horizontal scan passing through the central macula obtained by enhance-depth imaging mode of optical coherence tomography.

were measured separately by two independent masked clinicians (Yeter V and Kalyoncu M). The average of two measurements was used for the statistical analysis.

Statistical Analysis Data were statistically analyzed using SPSS V.22 software for Windows (SPSS Inc, Chicago, Illinois, USA). Mann-Whitney *U* test was used for comparison of the values between the androgen deficient and control groups.

Wilcoxon rank test was used to compare the values of the treatment group obtained at baseline and follow-up visits. Spearman correlation test was conducted to analyze the association of the choroidal parameters with other clinical variables. A *P*-value <0.05 indicated statistical significance.

RESULTS

The mean age of androgen deficient (24 males) and control (31 males) groups were 59.67±8.18y (range: 45–77y) and 60.74±6.34y (range: 48–73y), respectively. The characteristics of androgen deficient and control groups are summarized in Table 1. There is no statistically significant difference in the parameters of age, spherical equivalent, IOP, and presence of systemic disease (hypertension) between the groups (*P*>0.05). The values of CVI, C-SA, CSLR, CVI₁₅₀₀, C-LA₁₅₀₀, and CSLR₁₅₀₀ were significantly different between the patients with androgen deficiency and healthy controls (*P*<0.01 for all). The comparison of the parameters between the groups is shown in Table 2.

The means of serum testosterone levels in androgen deficient group treated with exogenous testosterone at baseline, 6th week, and 18th week were 205.0±28.9 (range: 95–231) ng/dL, 1251.1±217.7 (range: 831–1500) ng/dL, and 1283.3±223.3 (range: 1023–1500) ng/dL, respectively (Figure 2A). The mean SFCT of androgen deficient group was 307.7±27.0 μm (range: 263–361 μm) at baseline, and it decreased to 290.8±23.5 (range: 246–337) μm at 6th week of the exogenous testosterone

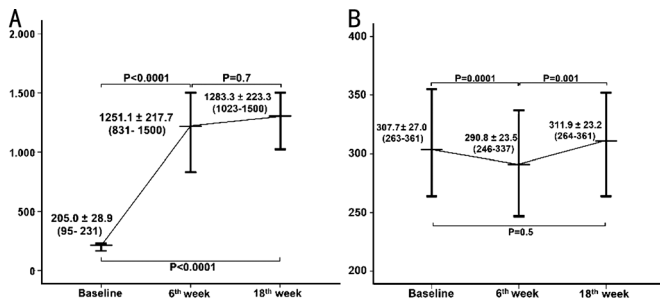


Figure 2 The changes in serum testosterone level (A) and subfoveal choroidal thickness (SFCT, B) of the androgen deficient group treated by exogenous testosterone therapy. The data are shown as mean±standard deviation (min–max).

treatment, and then, it increased to 311.9±23.2 (range: 264–361) µm at the 18th week of the treatment (Figure 2B). CVI, C-LA, C-SA, and C-SA₁₅₀₀ were significantly decreased at the 6th week of the testosterone treatment, but they returned to baseline levels at the 18th-week visit ($P>0.05$ for all; Figures 3 and 4).

CVI₁₅₀₀ and C-LA₁₅₀₀ significantly increased at the 18th-week visit, while CSLR₁₅₀₀ showed a significant decrease (Figure 4). The alterations in choroidal parameters of the patients with androgen deficiency treated with exogenous testosterone during the follow-up period were demonstrated in Figures 3 and 4.

DISCUSSION

Testosterone is a vasoactive hormone and plays an important role in vascular tonus *via* endothelium-dependent^[15] or independent mechanisms^[16]. The vascular effects of testosterone with different serum levels were previously shown for medium or large-size arteries in clinical and experimental studies^[16], however, there is no data about the direct effects of testosterone on choroidal vasculature. To the best of our knowledge, it is the first study reporting the differences in choroidal parameters between patients with androgen deficiency and healthy controls, and investigating the short-term alterations in the choroid due to exogenous testosterone. In the present study, we found that CVI was significantly lower in the androgen-deficient group than in healthy subjects, regardless of SFCT. Nevertheless, luminal/vascular components (C-LA₁₅₀₀) and CVI in the area of the central fovea within 1500 µm (CVI₁₅₀₀) were found significantly lower in the androgen-deficient group than in healthy subjects. The fovea is the most metabolically active area of the retina, and the choroid layer beneath the fovea is the thickest portion of the entire choroid. Testosterone has a vasorelaxation effect on vascular smooth muscle^[16], and it may be speculated that a longstanding lack of testosterone might cause an increase in vascular tonus of choroidal vasculature and this might be observed especially within the foveal region. Additionally, the choroid and the retinal pigment epithelium have androgen

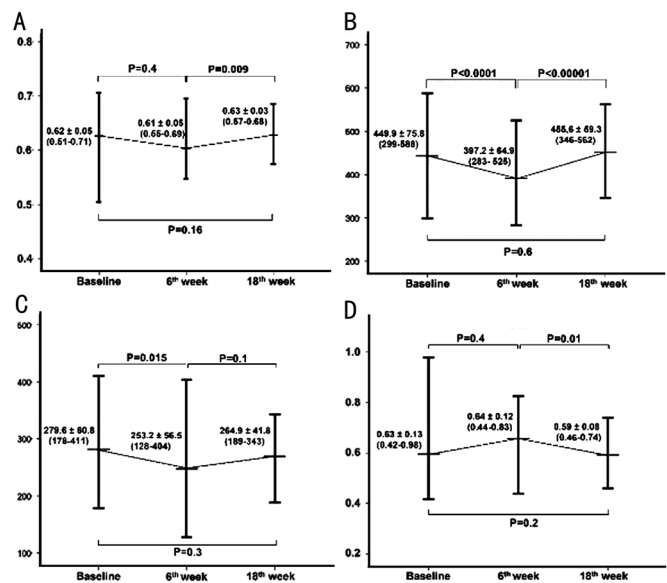


Figure 3 The alterations in the choroidal vascularity index (CVI, A), the choroidal luminal area (C-LA, B), the choroidal stromal area (C-SA, C), and the choroid-stromal to luminal area ratio (CSLR, D) of the patients with androgen deficiency due to testosterone replacement therapy were demonstrated in the line graphs with error bars. The data are shown as mean±standard deviation (min–max).

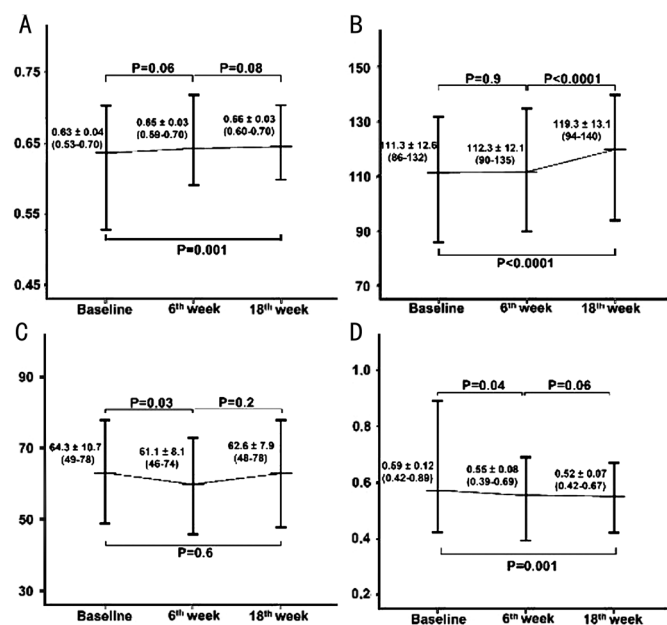


Figure 4 The alterations in choroidal parameters within 1500 µm of the central macula, including the choroidal vascularity index (CVI₁₅₀₀, A), the choroidal luminal area (C-LA₁₅₀₀, B), the choroidal stromal area (C-SA₁₅₀₀, C), and the choroid-stromal to luminal area ratio (CSLR₁₅₀₀, D) of the androgen deficient group due to exogenous testosterone therapy were demonstrated in the line graphs with error bars. The data are shown as mean±standard deviation (min–max).

receptors^[10], and it may result from differences in androgen receptor distribution or androgen susceptibility throughout the choroidal vasculature.

In the study, it was found that SFCT was significantly decreased at the 6th week of exogenous testosterone therapy

by 4 intramuscular injections, and it returned to baseline level at the 18th week of the treatment after 10 injections despite continued high serum testosterone level. Similar fluctuations were also seen in the values of CVI, C-LA, C-SA, and C-SA₁₅₀₀. It may be thought that high-dose exogenous testosterone might have vasoconstrictive effects during the period of early testosterone peak. Because Sader *et al*^[15] reported that high-dose exogenous testosterone is associated with decreased endothelium-dependent dilatation in androgen-deficient men treated with testosterone replacement therapy. Testosterone and estrogen influence endothelin-1 (ET-1) plasma levels, which is a potent vasoconstrictor, and higher testosterone level is associated with higher ET-1 plasma levels in contrast to higher estrogen levels in healthy subjects^[17]. However, Kumanov *et al*^[18] showed that ET-1 levels in androgen-deficient males were higher than the healthy controls and ET-1 levels were decreased after exogenous testosterone therapy. It may be thought that the significant decrease in central vascularity parameters (CVI₁₅₀₀ and CLA₁₅₀₀) of the androgen-deficient group may occur *via* the effects of higher ET-1 levels on the choroidal endothelium in patients with prolonged testosterone deprivation. In the present study, the fluctuations in SFCT and vascularity parameters during the treatment period may result from the alteration in vascular responsiveness. Because Jones *et al*^[19] reported that the decrease in vasodilation following testosterone treatment in hypogonadal men may only represent a restoration of vascular responsiveness rather than a loss of sensitivity to vasodilatory stimuli.

In addition to previously defined ion-channel modulation, testosterone can also affect endothelial function by the modulation of nitric oxide (NO) release^[20]. Circulating plasma testosterone is converted into 17 β -estradiol (E₂) by the enzyme P-450-aromatase (CYP19A1), and E₂ is well known to stimulate NO release that is a potent vasodilator^[20]. Serum E₂ level increases 24–48h after intramuscular testosterone injection in androgen-deficient men and returns to baseline 2wk after the injection^[21]. Testosterone is also converted into 5-reduced dihydro-metabolites (5 α - and 5 β -dihydro-testosterone) by the reductases besides E₂. Thus, the subjects always have higher serum androgen levels than physiological concentrations during the entire treatment period. After several injections every 2wk, serum levels of E₂ and androgen metabolites may reach a balance in terms of influence on choroidal vasculature at the 18th week of the testosterone treatment. However, CVI₁₅₀₀ and choroidal vascular components within the central 1500 μ m of the macula may increase while mean SFCT returned to baseline level. We found that CVI₁₅₀₀ and C-LA₁₅₀₀ values, which were significantly lower in the androgen deficient group at baseline, gradually

increased to values close to those of healthy individuals by androgen replacement treatment in the 18th week.

Agrawal *et al*^[14] speculated that the CVI could be a useful index for early choroidal alterations in the diagnosis of CSC. They showed that increased CVI compared to healthy subjects suggests an increased vascular component compared with the stromal component in acute CSC and increased CVI was also found in the fellow eye of the subjects with acute CSC. Despite the gradual increase in CVI and CVI₁₅₀₀, these have not even reached the level in healthy subjects at the 18th week of testosterone treatment. Thus, no patient developed CSC or pachychoroid spectrum diseases during the follow-up in the study.

The present study has some limitations. The retrospective design of the study may have caused selection bias, and it has a relatively small sample size. We have no data about the choroidal parameters for the period between the 6th and 18th weeks or the following period after 18wk of the androgen replacement therapy.

In conclusion, the androgen-deficient patients have significantly lower CVI values than the healthy subjects, although they have SFCT similar to the control group. Exogenous testosterone may have significant effects on the choroidal vasculature in short-term and longitudinal periods, and the changes in the choroid may be more prominent at the central 1500 μ m of the macula during the early weeks of testosterone replacement therapy in men with androgen deficiency. The clinicians may take into account these effects of exogenous testosterone in the treatment and follow-up of androgen-deficient patients with chorioretinal pathology. Prospective longitudinal follow-up studies should be scheduled to confirm the findings of the present study and to evaluate the longitudinal effects of exogenous testosterone in androgen-deficient subjects.

ACKNOWLEDGEMENTS

Conflicts of Interest: Yeter V, None; Koçak N, None; Kalyoncu M, None; Aşçı R, None; Arıtürk N, None.

REFERENCES

- 1 Nudleman E, Witmer MT, Kiss S, Williams GA, Wolfe JD. Central serous chorioretinopathy in patients receiving exogenous testosterone therapy. *Retina* 2014;34(10):2128-2132.
- 2 Conway MD, Noble JA, Peyman GA. Central serous chorioretinopathy in postmenopausal women receiving exogenous testosterone. *Retin Cases Brief Rep* 2017;11(2):95-99.
- 3 Ahad MA, Chua CN, Evans NM. Central serous chorioretinopathy associated with testosterone therapy. *Eye (Lond)* 2006;20(4):503-505.
- 4 Grieshaber MC, Staub JJ, Flammer J. The potential role of testosterone in central serous chorioretinopathy. *Br J Ophthalmol* 2007;91(1):118-119.
- 5 Brill D, Albert D, Fields T, Mikkilineni S, Crandall D, Gao H. Ciliochoroidal effusion syndrome with central serous-like chorioretinopathy

- and secondary angle closure following exogenous testosterone use. *Am J Ophthalmol Case Rep* 2019;15:100482.
- 6 Çiloğlu E, Unal F, Dogan NC. The relationship between the central serous chorioretinopathy, choroidal thickness, and serum hormone levels. *Graefes Arch Clin Exp Ophthalmol* 2018;256(6):1111-1116.
- 7 Marriott RJ, Murray K, Adams RJ, *et al.* Factors associated with circulating sex hormones in men: individual participant data meta-analyses. *Ann Intern Med* 2023;176(9):1221-1234.
- 8 Fung AT, Yang Y, Kam AW. Central serous chorioretinopathy: a review. *Clinical Exper Ophthalmology* 2023;51(3):243-270.
- 9 Toker E, Yenice Ö, Akpınar I, Aribal E, Kazokoglu H. The influence of sex hormones on ocular blood flow in women. *Acta Ophthalmol Scand* 2003;81(6):617-624.
- 10 Wickham LA, Gao J, Toda I, Rocha EM, Ono M, Sullivan DA. Identification of androgen, estrogen and progesterone receptor mRNAs in the eye. *Acta Ophthalmol Scand* 2000;78(2):146-153.
- 11 Fusi-Rubiano W, Saedon H, Patel V, Yang YC. Oral medications for central serous chorioretinopathy: a literature review. *Eye (Lond)* 2020;34(5):809-824.
- 12 Agrawal R, Ding JB, Sen P, *et al.* Exploring choroidal angioarchitecture in health and disease using choroidal vascularity index. *Prog Retin Eye Res* 2020;77:100829.
- 13 Kresch E, Patel M, Lima TFN, Ramasamy R. An update on the available and emerging pharmacotherapy for adults with testosterone deficiency available in the USA. *Expert Opin Pharmacother* 2021;22(13):1761-1771.
- 14 Agrawal R, Chhablani J, Tan KA, Shah S, Sarvaiya C, Banker A. Choroidal vascularity index in central serous chorioretinopathy. *Retina* 2016;36(9):1646-1651.
- 15 Sader MA, Griffiths KA, Skilton MR, Wishart SM, Handelsman DJ, Celermajer DS. Physiological testosterone replacement and arterial endothelial function in men. *Clin Endocrinol* 2003;59(1):62-67.
- 16 Perusquía M, Stallone JN. Do androgens play a beneficial role in the regulation of vascular tone? Nongenomic vascular effects of testosterone metabolites. *Am J Physiol Heart Circ Physiol* 2010;298(5):H1301-H1307.
- 17 Torres Crigna A, Link B, Samec M, Giordano FA, Kubatka P, Golubnitschaja O. Endothelin-1 axes in the framework of predictive, preventive and personalised (3P) medicine. *EPMAJ* 2021;12(3):265-305.
- 18 Kumanov P, Tomova A, Kirilov G. Testosterone replacement therapy in male hypogonadism is not associated with increase of endothelin-1 levels. *Int J Androl* 2007;30(1):41-47.
- 19 Jones RD, Hugh Jones T, Channer KS. The influence of testosterone upon vascular reactivity. *Eur J Endocrinol* 2004;29-37.
- 20 Miller MR, Megson IL. Recent developments in nitric oxide donor drugs. *Br J Pharmacol* 2007;151(3):305-321.
- 21 Nakazawa R, Baba K, Nakano M, Katabami T, Saito N, Takahashi T, Iwamoto T. Hormone profiles after intramuscular injection of testosterone enanthate in patients with hypogonadism. *Endocr J* 2006;53(3):305-310.