

# Dexamethasone implant for refractory macular edema secondary to diabetic retinopathy and retinal vein occlusion

Yuan–Yuan Zhong, Chong Tang, Lan–Yue Zhang, Xue–Dong Zhang, Shu–Lin Liu

The First Affiliated Hospital of Chongqing Medical University, Chongqing Key Laboratory for the Prevention and Treatment of Major Blinding Eye Diseases, Chongqing 400016, China

**Correspondence to:** Shu-Lin Liu. The First Affiliated Hospital of Chongqing Medical University, Youyi Road 1, Yuzhong District, Chongqing 400016, China. shulinliu\_cmu@163.com

Received: 2023-09-15 Accepted: 2024-03-19

## Abstract

• **AIM:** To evaluate the efficacy, timing of retreatment and safety of dexamethasone (DEX) implant on macular edema (ME) secondary to diabetic retinopathy (DME) and retinal vein occlusion (RVO-ME) patients who were refractory to anti-vascular endothelial growth factor (VEGF) treatment.

• **METHODS:** This retrospective study included 37 eyes received at least one DEX implant treatment for DME or RVO-ME between January 1, 2019, and January 1, 2023. These refractory DME and RVO-ME cases received at least 5 anti-VEGF injections and failure to gain more than 5 letters or a significant reduction in central retinal thickness (CRT). The best corrected visual acuity (BCVA) and CRT were measured at baseline, and at 1, 3, 4 and 6mo post-DEX implant injection. Adverse events such as elevated intraocular pressure (IOP) and cataract were recorded.

• **RESULTS:** For RVO cases ( $n=22$ ), there was a significant increase in BCVA from  $0.27\pm 0.19$  to  $0.35\pm 0.20$  at 6mo post-DEX injection ( $P<0.05$ ) and CRT decreased from  $472.1\pm 90.6$  to  $240.5\pm 39.0$   $\mu\text{m}$  at 6mo ( $P<0.0001$ ). DME cases ( $n=15$ ) experienced an improvement in BCVA from  $0.26\pm 0.15$  to  $0.43\pm 0.20$  at 6mo post-DEX implant injection ( $P=0.0098$ ), with CRT reducing from  $445.7\pm 55.7$  to  $271.7\pm 34.1$   $\mu\text{m}$  at 6mo ( $P<0.0001$ ). Elevated IOP occurred in 45.9% of patients but was well-controlled with topical medications. No cases of cataract or other adverse events were reported.

• **CONCLUSION:** DEX implants effectively improve BCVA and reduce CRT in refractory DME and RVO-ME. Further research with larger cohorts and longer follow-up periods is needed to confirm these findings and assess long-term outcomes.

• **KEYWORDS:** macular edema; dexamethasone implant; anti-vascular endothelial growth factor; retinal vein occlusion; diabetic retinopathy

**DOI:**10.18240/ijo.2024.10.09

**Citation:** Zhong YY, Tang C, Zhang LY, Zhang XD, Liu SL. Dexamethasone implant for refractory macular edema secondary to diabetic retinopathy and retinal vein occlusion. *Int J Ophthalmol* 2024;17(10):1837-1842

## INTRODUCTION

Macular edema (ME) is a prevalent cause of visual impairment associated with retinal vein occlusion (RVO), diabetic retinopathy (DR) and many other diseases<sup>[1-3]</sup>. It has significant impact on patient's quality of life. The pathogenesis of ME is intricate and multifactorial, with inflammation playing a pivotal role among various contributing factors<sup>[4-6]</sup>. In recent years, vascular endothelial growth factor (VEGF) inhibitors emerged as the first-line therapeutic option, offering potential improvements in anatomical outcomes, notably a reduction in central retinal thickness (CRT), as well as enhancements in visual acuity<sup>[7-10]</sup>. Nevertheless, a substantial proportion of patients fail to achieve adequate responses<sup>[2,11]</sup>. The current scientific evidence suggests that a substantial portion of macular edema patients do not exhibit an adequate response to anti-VEGF treatment<sup>[2,10,12]</sup>, as it does not suppress all the inflammatory process involved in ME patients<sup>[13]</sup>.

Steroids, with their well-established anti-angiogenic and anti-hyperpermeability properties, have been employed in treating ocular inflammation. Their primary effect is believed to involve stabilizing the blood-retinal barrier by suppressing VEGF-mediated neovascularization and the response to inflammatory triggers, although the precise mechanism remains elusive<sup>[14]</sup>. Ozurdex is a biodegradable intravitreal implant containing sustained-release dexamethasone (DEX). It is designed to release 700 mg of medication over a six-month period, with peak concentration occurring around the second month. Emerging evidence indicates that DEX could

represent a valuable alternative for patients who have not responded satisfactorily to anti-VEGF injections<sup>[15-21]</sup>. Well-documented side effects of steroid include cataracts and elevated intraocular pressure (IOP)<sup>[20,22]</sup>. It is traditionally used as second-line therapy in the management of diabetic macular edema (DME) and RVO-macular edema (RVO-ME) due to the aforementioned side effects<sup>[19,23-28]</sup>. DEX also offers potential advantages beyond its role in controlling inflammation, such as a reduction of anti-VEGF tachyphylaxis. Therefore, we carried out a retrospective study to evaluate the real-world application of the DEX implant in refractory DME and RVO-ME patients. This study aims to assess the DEX's efficacy up to six months post-surgery and determine the necessity and timing of retreatments.

**SUBJECTS AND METHODS**

**Ethical Approval** The study was conducted in accordance with the Declaration of Helsinki, and approved by the Institutional Review Board of the First Affiliated Hospital of Chongqing Medical University (approval reference number: 2023-057). Informed consent was obtained from all subjects involved in the study.

We searched patients in the database from two ophthalmologist (Zhang XD and Liu SL) who had previously received at least one DEX implant treatment for DME or RVO-ME between January 1, 2019, and January 1, 2023. Among them, we included refractory DME and RVO-ME patients who have received at least 5 anti-VEGF injections. Refractory ME was defined as failure to gain 5 letters or a significant reduction in CRT after 5 injections. They should not have had any other ocular disorder affecting visual acuity. Patients with ME arising from other conditions were excluded.

Best corrected visual acuity (BCVA) and CRT [Heidelberg Spectralis optical coherence tomography (OCT)] were recorded before the initiation of any anti-VEGF or DEX therapy, prior to DEX switch, and at 1, 3, 4, and 6mo post-DEX implant injection. After DEX implant injection, retreatment was carried out if CRT>300 μm or if BCVA decreased due to recurrence of ME. Adverse events such as elevated intraocular pressure (IOP), cataract, endophthalmitis, and retinal detachment were recorded.

**Statistical Analysis** Statistical analysis was performed using SPSS 23.0 software and GraphPad Prism 8. For descriptive data such as BCVA, age, and IOP, statistics were calculated using mean±standard deviation (SD). The Tukey's multiple comparisons test, a post-hoc analysis following ANOVA, was utilized to conduct pairwise comparisons among BCVA and CRT measurements at different time points. Statistical significance was set at *P*<0.05.

**RESULTS**

Thirty-seven treated eyes (37 patients) were included. In cases

**Table 1 Characteristics of the included patients**

Parameters	DME (n=15)	RVO-ME (n=22)
Gender (male)	8	13
Age, y (mean±SD)	55.3±12.8	61.5±13.2
Anti-VEGF injections, <i>n</i>	6.6±1.9	6.1±1.4
Ranibizumab, <i>n</i> (%)	17 (17.2)	114 (84.4)
Conbercept, <i>n</i> (%)	63 (63.6)	15 (11.1)
Aflibercept, <i>n</i> (%)	19 (19.2)	6 (4.4)
Duration between disease onset and the switch of medication, mo (mean±SD)	8.7±2.5	8.5±2.0

VEGF: Vascular endothelial growth factor; DME: Diabetic macular edema; RVO-ME: Retinal vein occlusion-macular edema; SD: Standard deviation.

of RVO (*n*=22), there were 13 male and 9 female patients, with a mean age of 61.5±13.2y. For DME (*n*=15), there were 8 male and 7 female patients, with a mean age of 55.3±12.8y. DME patients received 6.6±1.9 injections of anti-VEGF, among them, 63.6% were conbercept. RVO-ME patients received 6.1±1.4 injections of anti-VEGF, among them, 84.4% were ranibizumab. The time duration between disease onset and the switch of anti-VEGF to DEX was 8.7±2.5mo for DME patients, and 8.5±2.0mo for RVO-ME patients (Table 1).

Overall, at the 3-month post DEX implant injection, 14 patients (40%) required retreatment with DEX implant. Among them, there were 9 DME patients and 5 RVO-ME patients. By the time of 6mo, 5 patients needed retreatment.

**Retinal Vein Occlusion-Macular Edema Patients** At baseline, patients with RVO-ME (*n*=22) had a mean BCVA of 0.24±0.17 and CRT of 548.0±141.7 μm. Prior to switching to DEX treatment, the BCVA was 0.27±0.19 (*P*>0.05). However, CRT decreased to 472.1±90.6 μm when compared to the baseline (*P*=0.0072). After receiving DEX implant treatment, there was a notable improvement in BCVA at the end of 1, 3, 4, and 6mo (*P*=0.0001, 0.0023, 0.0204, and 0.0102, respectively; Figure 1A). However, there was no additional increase in visual acuity at months 3, 4, and 6 when compared to month 1. CRT continued to show a significant reduction at months 1, 3, 4, and 6 after the injection (all *P*<0.0001; Figure 1B), reaching 240.5±39.0 μm by month 6. At 3mo, 23% of the patients (*n*=5) required retreatment with the DEX implant, and by 6mo, an additional 2 patients need retreatment. The mean time interval until retreatment was 3.9±1.5mo.

**Diabetic Macular Edema** Patients with DME had a mean BCVA of 0.26±0.15 and CRT of 463.6±97.6 μm. Prior to switching to DEX, BCVA was 0.26±0.15, and CRT was 445.7±55.7 μm. None of these measurements showed statistically significant differences when compared to the baseline. Following DEX implant treatment, there was an improvement in BCVA at the 1, 3, 4, and 6mo compared to

**Table 2 IOP changes during the follow-up in DME and RVO-ME patients** mm Hg, mean±SD

Patients	Baseline	Post-DEX				Elevated IOP, n (%)
		1mo	3mo	4mo	6mo	
DME	16.5±3.9	18.1±4.1	20.4±5.0	22.3±4.3	16.4±4.3	7 (46.7)
RVO-ME	16.2±3.3	17.9±3.7	20.1±5.3	21.1±5.3	15.9±3.6	10 (45.5)

IOP: Intraocular pressure; DME: Diabetic macular edema; RVO-ME: Retinal vein occlusion-macular edema; DEX: Dexamethasone.

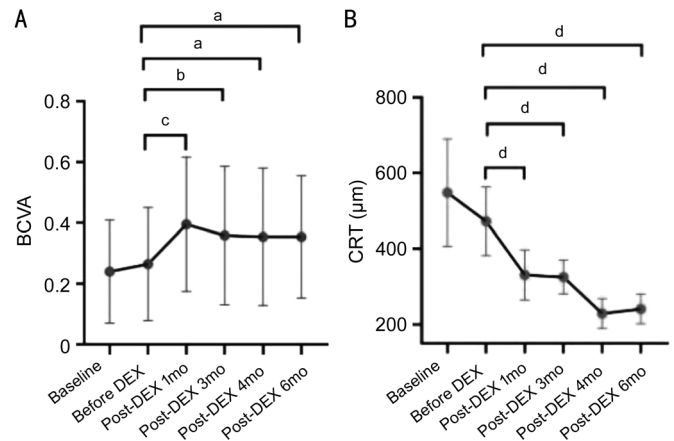
pre-DEX injection levels ( $P=0.0398, 0.0009, 0.0012,$  and  $0.0098,$  respectively; Figure 2A). However, there was no additional increase at months 3, 4, and 6 when compared to month 1. Additionally, CRT exhibited a significant reduction at months 1, 3, 4, and 6 following the injection (all  $P<0.0001,$  respectively; Figure 2B). At 3mo, 60% of the patients ( $n=9$ ) required retreatment with the DEX implant, and by 6mo, an additional 3 patients needed retreatment. The mean time interval until retreatment was  $3.52\pm 1.2$ mo.

**Safety** The changes of IOP before and after DEX injection for both DME and RVO-ME patients were shown in Table 2. Overall, 45.9% (17/37) of patients experienced elevated IOP ( $>25$  mm Hg) during the follow-up. The IOP was well controlled using topical medications in these patients. None of the patients required glaucoma surgery. No cases of newly developed cataract, endophthalmitis, or retinal detachment were reported.

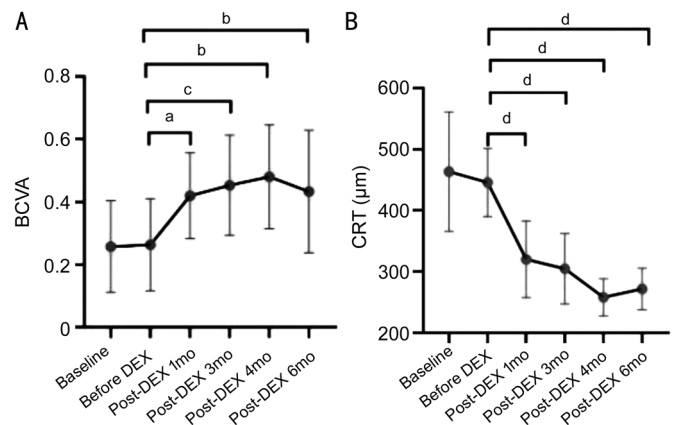
**DISCUSSION**

This study provides a real-world evidence of the clinical efficacy and safety of DEX implants in treating anti-VEGF refractory DME and RVO-ME patients. The results demonstrate statistically significant improvements in BCVA and CRT following treatment with DEX implants across the two groups. These findings were consistent with previous studies reporting the positive impact of DEX implants on ME and support their use in patients unresponsive to anti-VEGF therapy.

A Meta-analysis compared intravitreal aflibercept and DEX implant for DME and RVO-ME, incorporating data from seven studies and 369 eyes. The results indicate both treatments effectively improve BCVA and reduce CRT with no significant difference at 3 and 12mo<sup>[29]</sup>. However, the study did not mention if these patients were treatment naive or had refractory macular edema. Mitchell *et al*<sup>[30]</sup> evaluated the effectiveness of DEX in refractory DME patients who did not respond to previous 3-6 injections of anti-VEGF. Their findings revealed that following the transition from anti-VEGF agents to DEX, there was a significant reduction in CRT at 52wk, and no new safety concerns emerged. A prospective, interventional case series involved 13 refractory DME patients, the results showed that they received an average of 2.2 DEX injections during 1y. At week 52, there were statistically significant improvements in both visual acuity and CRT<sup>[31]</sup>. Maturi *et al*<sup>[32]</sup> conducted a



**Figure 1 BCVA (A) and CRT (B) changes in RVO-ME patients before and after DEX implant** BCVA: Best corrected visual acuity; CRT: Central retinal thickness; RVO-ME: Retinal vein occlusion-macular edema; DEX: Dexamethasone. <sup>a</sup> $P<0.05,$  <sup>b</sup> $P<0.01,$  <sup>c</sup> $P<0.001,$  <sup>d</sup> $P<0.0001.$



**Figure 2 BCVA (A) and CRT (B) changes in DME patients before and after DEX implant** BCVA: Best corrected visual acuity; CRT: Central retinal thickness; DME: Diabetic macular edema; DEX: Dexamethasone. <sup>a</sup> $P<0.05,$  <sup>b</sup> $P<0.01,$  <sup>c</sup> $P<0.001,$  <sup>d</sup> $P<0.0001.$

study comparing the efficacy of combination therapy with DEX and bevacizumab versus monthly bevacizumab monotherapy in patients with refractory DME who had received multiple bevacizumab injections. After 12mo, the combination group required a mean of 2.1 DEX injections and 9 bevacizumab injections, which was nearly identical to the monotherapy group. The combination group exhibited a greater reduction in CRT compared to the monotherapy group, although both groups showed similar improvements in visual acuity. These findings suggested a potential beneficial effect of using the DEX implant when anti-VEGF agents have limited efficacy.

As there is currently no universally agreed-upon definition for treatment resistance in DME<sup>[33]</sup>, variations in the definitions employed across different studies may also contribute to the observed variability in outcomes. After switching to DEX in refractory RVO-ME cases, significant improvements in visual acuity and a notable reduction in CRT can also be achieved<sup>[34]</sup>. Ou *et al*<sup>[35]</sup> found a convincing relationship between visual acuity and CRT in refractory DME patients who received anti-VEGF treatment. However, correlations appear to be more complex in patients with RVO-ME. Danis *et al*<sup>[36]</sup> analyzed two clinical trials of DEX implant for RVO-ME, and found a statistically significant negative linear correlation between changes in CRT and changes in visual acuity. In our analysis, however, despite continuous improvements in CRT, there was no corresponding further improvement in visual function after month 1 post-DEX injection. In our study, the patients had undergone multiple intravitreal anti-VEGF before switching to the rescue treatment of DEX. The average disease duration of before DEX implant injection was approximately 8mo in our study, while the patients in Ou *et al*<sup>[35]</sup> and Danis *et al*<sup>[36]</sup> studies had a shorter disease duration before DEX treatment. Therefore, the refractory and chronic nature of the disease may explain why the visual acuity were not correlated with the anatomical changes. In both DME and RVO-ME patients, chronic retinal ischemia may play a role in the damage of the photoreceptor cells. In RVO patients, acute retinal ischemia can also lead to sudden accumulation of retinal fluid without compensatory. Even though anti-VEGF or DEX injection can result in the absorption of fluid, the damage of hypoxia will be permanent. In DME patients, apart from macular edema, diabetic retinal neurodegeneration can also aggregate the functional outcome. Consequently, although there was a reduction in CRT, there was no aligned increase in visual acuity.

Therefore, researchers recommend early identification of refractory DME and a swift transition to DEX treatment for a more substantial improvement in vision. Mitchell *et al*<sup>[30]</sup> categorized the refractory DME patients into two groups: those who switched to DEX early, and those who switched late. They found that compared with late switch patients, the early-switch ones experienced a statistically significant improvement in visual acuity at week 52. Moreover, the proportion of patients with central foveal lipid deposits decreased by 50% among early switchers and 26% among late switchers, further suggesting the potential benefits of early switching. Other studies also support the prompt transition to DEX treatment in cases of inadequate response to three anti-VEGF injections in both DME and RVO-ME<sup>[15,18,37-39]</sup>. However, randomized clinical trials and Meta-analyses were eagerly anticipated to provide more guidance for clinical practice.

The need for retreatment with DEX implants varied among the patient groups, almost all the DME patients need retreatment at month 3. This suggests that the duration of ME control with a single DEX implant varies depending on the underlying etiology. Zandi *et al*<sup>[40]</sup> assessed the effect of repeated injections of DEX in 34 refractory DME patients and found that the mean time to reinjection was 4.6±0.5mo. DEX demonstrated a favorable long-term improvement both anatomically and functionally. In refractory RVO-ME patients, reinjection of DEX was also needed. Wallsh *et al*<sup>[41]</sup> found that in their study, the patients received 3 injections during 1y of follow-up. Therefore, these findings alongside with our study highlight the importance of ongoing monitoring and retreatment to maintain ME control.

The adverse events in this study were mainly IOP elevation. Topical glaucoma medication was prescribed for 45.9% of our patients. A randomized, multicenter study evaluated DEX in 1048 DME patients. It showed that 42% of them require IOP-lowering drops<sup>[42]</sup>, which was consistent with this study. Another study showed that approximately 20% to 25% of all study eyes experienced an increase in IOP of at least 10 mm Hg<sup>[43]</sup>, and most of the transient increase in IOP happened at month 2. The study also demonstrated that there was no cumulative impact on IOP over a three-year duration<sup>[42]</sup>.

This study had limitations including small sample size and retrospective design. Many prospective studies on ME typically do not include refractory ME. In contrast, our patients had chronic refractory ME, providing valuable real-world clinical insights for healthcare professionals.

In conclusion, our study demonstrates the effectiveness of DEX implants in improving visual acuity and reducing CRT in patients with refractory ME. While retreatment may be required in some cases, DEX implants offer a valuable treatment option for patients unresponsive to anti-VEGF therapy. Ongoing monitoring for IOP elevation is important to ensure patient safety. Further research with larger cohorts and longer follow-up periods is essential to confirm these results and assess the enduring impacts of the DEX implant on refractory ME. Additionally, it is crucial to establish a clear definition for refractory ME to determine the optimal timing for transitioning from anti-VEGF treatments to DEX. This approach aims to maximize patient benefits while minimizing side effects and financial costs.

#### **ACKNOWLEDGEMENTS**

The authors thank staff members from The First Affiliated Hospital of Chongqing Medical University for their assistance with information collection.

**Authors' contributions:** Conceptualization, Liu SL; methodology, Tang C; formal analysis, Zhong YY; investigation, Zhong YY; data curation, Zhang LY; writing—



original draft preparation, Liu SL; writing—review and editing, Zhang XD; funding acquisition, Zhang XD, Liu SL, and Zhong YY. All authors have read and agreed to the final version of the manuscript.

**Foundations:** Supported by the National Natural Science Found of China (No.81870673; No.81800814; No.82201168).

**Conflicts of Interest:** Zhong YY, None; Tang C, None; Zhang LY, None; Zhang XD, None; Liu SL, None.

#### REFERENCES

- 1 Boscia F, Veritti D, Iaculli C, Lattanzio R, Freda S, Piergentili B, Varano M. Management of treatment-naïve diabetic macular edema patients: review of real-world clinical data. *Eur J Ophthalmol* 2024;11206721241237069. Epub ahead of print.
- 2 Hunter A, Williams M. Long-term outcomes for patients treated for macular oedema secondary to retinal vein occlusion: a systematic review. *BMJ Open Ophthalmol* 2022;7(1):e001010.
- 3 Zhang J, Zhang J, Zhang C, Zhang J, Gu L, Luo D, Qiu Q. Diabetic macular edema: current understanding, molecular mechanisms and therapeutic implications. *Cells* 2022;11(21):3362.
- 4 Zeng Y, Wen F, Zhuang X, He G, Zhang X. Epiretinal macrophage-like cells on optical coherence tomography: potential inflammatory imaging biomarker of severity in diabetic retinopathy. *Retina* 2024;44(8):1314-1322.
- 5 Lai DW, Wu Y, Shao CH, Qiu QH. The role of Müller cells in diabetic macular edema. *Invest Ophthalmol Vis Sci* 2023;64(10):8.
- 6 Yenihayat F, Özkan B, Kasap M, Karabaş VL, Güzel N, Akpınar G, Pirhan D. Vitreous IL-8 and VEGF levels in diabetic macular edema with or without subretinal fluid. *Int Ophthalmol* 2019;39(4):821-828.
- 7 Zur D, Hod K, Trivizki O, Rabinovitch D, Schwartz S, Shulman S. Anti-vascular endothelial growth factor treatment in diabetic macular edema: results from a large single-center cohort with bevacizumab as first-line therapy. *Retina* 2024;44(8):1305-1313.
- 8 Virgili G, Curran K, Lucenteforte E, Peto T, Parravano M. Anti-vascular endothelial growth factor for diabetic macular oedema: a network meta-analysis. *Cochrane Database Syst Rev* 2023;2023(6):CD007419.
- 9 Johari M, Attar A, Eghtedari D, Razavizadegan SA. Characteristics of macular edema associated with retinal vein occlusion showing poor anatomic response to three loading anti-vascular endothelial growth factor injections: an optical coherence tomography analysis. *BMC Ophthalmol* 2024;24(1):30.
- 10 Bakri SJ, Delyfer MN, Grauslund J, Andersen S, Karcher H. Real-world persistence and treatment interval in patients with diabetic macular edema treated with anti-vascular endothelial growth factors in the USA. *Ophthalmol Ther* 2023;12(5):2465-2477.
- 11 Gabrielle PH, Mehta H, Barthelmes D, Daien V, Nguyen V, Gillies MC, Creuzot-Garcher CP. From randomised controlled trials to real-world data: Clinical evidence to guide management of diabetic macular oedema. *Prog Retin Eye Res* 2023;97:101219.
- 12 Dugel PU, Campbell JH, Kiss S, Loewenstein A, Shih V, Xu X, Holekamp NM, Augustin AJ, Ho AC, Gonzalez VH, Whitcup SM. Association between early anatomic response to anti-vascular endothelial growth factor therapy and long-term outcome in diabetic macular edema: an independent analysis of Protocol I Study Data. *Retina* 2019;39(1):88-97.
- 13 Vofo BN, Chowers I. Suppressing inflammation for the treatment of diabetic retinopathy and age-related macular degeneration: dazdotuftide as a potential new multitarget therapeutic candidate. *Biomedicines* 2023;11(6):1562.
- 14 Sarao V, Veritti D, Boscia F, Lanzetta P. Intravitreal steroids for the treatment of retinal diseases. *Sci World J* 2014;2014:989501.
- 15 Hernández Martínez A, Pereira Delgado E, Silva Silva G, Castellanos Mateos L, Lorente Pascual J, Lainez Villa J, García Vicente P, Almeida-González CV. Early versus late switch: How long should we extend the anti-vascular endothelial growth factor therapy in unresponsive diabetic macular edema patients? *Eur J Ophthalmol* 2020;30(5):1091-1098.
- 16 Cicinelli MV, Cavalleri M, Querques L, Rabiolo A, Bandello F, Querques G. Early response to ranibizumab predictive of functional outcome after dexamethasone for unresponsive diabetic macular oedema. *Br J Ophthalmol* 2017;101(12):1689-1693.
- 17 Busch C, Zur D, Fraser-Bell S, Láins I, Santos AR, Lupidi M, Cagini C, Gabrielle PH, Couturier A, Mané-Tauty V, Giampoli E, Ricci GD, Cebezi Z, Rodríguez-Valdés PJ, Chaikitmongkol V, Amphornphruet A, Hindi I, Agrawal K, Chhablani J, Loewenstein A, Igllicki M, Rehak M; International Retina Group. Shall we stay, or shall we switch? Continued anti-VEGF therapy versus early switch to dexamethasone implant in refractory diabetic macular edema. *Acta Diabetol* 2018;55(8):789-796.
- 18 Demir G, Ozkaya A, Yuksel E, Erdogan G, Tunc U, Celal Ocal M, Sakır Goker Y. Early and late switch from ranibizumab to an intravitreal dexamethasone implant in patients with diabetic macular edema in the event of a poor anatomical response. *Clin Drug Investig* 2020;40(2):119-128.
- 19 Kumar A, Kumar A, Kumar J, Bai G, Jeewnani R, Dembra M, Kanwal K, Qadeer U, Khawar MH, Khan IY, Ram R, Varrassi G. Comparative efficacy of anti-vascular endothelial growth factor (anti-VEGF) agents and corticosteroids in managing diabetic retinopathy-associated diabetic macular edema: a meta-analysis and comprehensive systematic review. *Cureus* 2024;16(1):e51910.
- 20 Wei W, Chen Y, Hu B, Zhao M, Han M, Dai H, Uy HS, Chen MY, Wang K, Jiao J, Lou J, Li X. Multicenter, prospective, randomized study of dexamethasone intravitreal implant in patients with center-involved diabetic macular edema in the Asia-Pacific Region. *Clin Ophthalmol* 2021;15:4097-4108.
- 21 Kodjikian L, Delcourt C, Creuzot-Garcher C, Massin P, Conrath J, Velard MÈ, Lassalle T, Pinchinat S, Dupont-Benjamin L. Prospective, observational, multicenter, real-world study of the efficacy, safety, and pattern of use of the dexamethasone intravitreal implant in diabetic macular edema in France: short-term outcomes of LOUVRE 3. *Ophthalmol Ther* 2023;12(3):1671-1692.

- 22 Chakraborty S, Ganguly S, Sheth JU. Role of intravitreal dexamethasone implant in the management of treatment-naïve diabetic macular edema: a pre-cataract surgical approach for patients with systemic contraindications to anti-VEGF therapy. *Clin Ophthalmol* 2024;18:227-233.
- 23 Chhablani J, Bansal P, Veritti D, Sambhana S, Sarao V, Pichi F, Carrai P, Massaro D, Lembo A, Mansour AM, Banker A, Gupta SR, Hamam R, Lanzetta P. Dexamethasone implant in diabetic macular edema in real-life situations. *Eye (Lond)* 2016;30(3):426-430.
- 24 Malclès A, Dot C, Voirin N, Agard É, Vié AL, Bellocq D, Denis P, Kodjikian L. Real-life study in diabetic macular edema treated with dexamethasone implant. *Retina* 2017;37(4):753-760.
- 25 Pareja-Ríos A, Ruiz-de la Fuente-Rodríguez P, Bonaque-González S, López-Gálvez M, Lozano-López V, Romero-Aroca P. Intravitreal dexamethasone implants for diabetic macular edema. *Int J Ophthalmol* 2018;11(1):77-82.
- 26 Nagpal M, Mehrotra N, Juneja R, Jain H. Dexamethasone implant (0.7 mg) in Indian patients with macular edema: real-life scenario. *Taiwan J Ophthalmol* 2018;8(3):141-148.
- 27 Medina-Baena M, Cejudo-Corbalán O, Labella-Quesada F, Girela-López E. Cost-effectiveness of dexamethasone intravitreal implant in Naïve and previously treated patients with diabetic macular edema. *Int J Environ Res Public Health* 2023;20(8):5462.
- 28 Horozoglu F, Sener H, Polat OA, Temizyurek O, Evereklioglu C. Predictive impact of optical coherence tomography biomarkers in anti-vascular endothelial growth factor resistant macular edema treated with dexamethasone implant. *Photodiagnosis Photodyn Ther* 2023;42:103167.
- 29 Qiu XY, Hu XF, Qin YZ, Ma JX, Liu QP, Qin L, Li JM. Comparison of intravitreal aflibercept and dexamethasone implant in the treatment of macular edema associated with diabetic retinopathy or retinal vein occlusion: a Meta-analysis and systematic review. *Int J Ophthalmol* 2022;15(9):1511-1519.
- 30 Mitchell P, Arnold J, Fraser-Bell S, Kang HK, Chang AA, Tainton J, Simonyi S. Dexamethasone intravitreal implant in diabetic macular oedema refractory to anti-vascular endothelial growth factors: the AUSSIEDEX study. *BMJ Open Ophthalmol* 2023;8(1):e001224.
- 31 Iacono P, Parodi MB, Scaramuzzi M, Bandello F. Morphological and functional changes in recalcitrant diabetic macular oedema after intravitreal dexamethasone implant. *Br J Ophthalmol* 2017;101(6):791-795.
- 32 Maturi RK, Bleau L, Saunders J, Mubasher M, Stewart MW. A 12-month, single-masked, randomized controlled study of eyes with persistent diabetic macular edema after multiple anti-vegf injections to assess the efficacy of the dexamethasone-delayed delivery system as an adjunct to bevacizumab compared with continued bevacizumab monotherapy. *Retina* 2015;35(8):1604-1614.
- 33 Bahrami B, Zhu M, Hong T, Chang A. Diabetic macular oedema: pathophysiology, management challenges and treatment resistance. *Diabetologia* 2016;59(8):1594-1608.
- 34 Teja S, Sawatzky L, Wiens T, Maberley D, Ma P. Ozurdex for refractory macular edema secondary to diabetes, vein occlusion, uveitis and pseudophakia. *Can J Ophthalmol* 2019;54(5):540-547.
- 35 Ou WC, Brown DM, Payne JF, Wyckoff CC. Relationship between visual acuity and retinal thickness during anti-vascular endothelial growth factor therapy for retinal diseases. *Am J Ophthalmol* 2017;180:8-17.
- 36 Danis RP, Sadda S, Jiao J, Li XY, Whitcup SM. Relationship between retinal thickness and visual acuity in eyes with retinal vein occlusion treated with dexamethasone implant. *Retina* 2016;36(6):1170-1176.
- 37 Busch C, Fraser-Bell S, Igllick M, et al. Real-world outcomes of non-responding diabetic macular edema treated with continued anti-VEGF therapy versus early switch to dexamethasone implant: 2-year results. *Acta Diabetol* 2019;56(12):1341-1350.
- 38 García Layana A, Adán A, Ascaso FJ, et al. Use of intravitreal dexamethasone implants in the treatment of diabetic macular edema: expert recommendations using a Delphi approach. *Eur J Ophthalmol* 2020;30(5):1042-1052.
- 39 Ruiz-Medrano J, Rodríguez-Leor R, Almazán E, Lugo F, Casado-Lopez E, Arias L, Ruiz-Moreno JM. Results of dexamethasone intravitreal implant (Ozurdex) in diabetic macular edema patients: early versus late switch. *Eur J Ophthalmol* 2021;31(3):1135-1145.
- 40 Zandi S, Lereuil T, Freiberg F, Pfau M, Pfister IB, Gerhardt C, Michels S, Kodjikian L, Garweg JG. Long-term intravitreal dexamethasone treatment in eyes with pretreated chronic diabetic macular edema. *J Ocul Pharmacol Ther* 2017;33(8):620-628.
- 41 Wallsh J, Sharareh B, Gallemore R. Therapeutic effect of dexamethasone implant in retinal vein occlusions resistant to anti-VEGF therapy. *Clin Ophthalmol* 2016;10:947-954.
- 42 Maturi RK, Pollack A, Uy HS, Varano M, Gomes AM, Li XY, Cui H, Lou J, Hashad Y, Whitcup SM, Ozurdex MEAD Study Group. Intraocular pressure in patients with diabetic macular edema treated with dexamethasone intravitreal implant in the 3-year mead study. *Retina* 2016;36(6):1143-1152.
- 43 Lam WC, Albani DA, Yoganathan P, Chen JC, Kherani A, Maberley DA, Oliver A, Rabinovitch T, Sheidow TG, Tourville E, Wittenberg LA, Sigouin C, Baptiste DC. Real-world assessment of intravitreal dexamethasone implant (0.7 mg) in patients with macular edema: the CHROME study. *Clin Ophthalmol* 2015;9:1255-1268.