

Bilateral meibomian gland morphological alterations in unilateral herpes simplex keratitis based on artificial intelligence analysis

Xin-Xin Yu, Xue-Wen Chen, Qi Dai, Shuang-Qing Wu

National Clinical Research Center for Ocular Diseases, Eye Hospital, Wenzhou Medical University, Wenzhou 325027, Zhejiang Province, China

Correspondence to: Qi Dai and Shuang-Qing Wu. National Clinical Research Center for Ocular Diseases, Eye Hospital, Wenzhou Medical University, Wenzhou 325027, Zhejiang Province, China. dq@mail.eye.ac.cn; shuangqingwu@zju.edu.cn
Received: 2023-12-06 Accepted: 2024-08-01

Abstract

• **AIM:** To explore whether unilateral herpes simplex keratitis (HSK) can cause morphological changes of bilateral meibomian glands (MGs) based on artificial intelligence (AI) analytical system.

• **METHODS:** In the retrospective study, 29 patients with unilateral HSK and 29 participants matched in terms of age and sex were included as control group. Meibographic images of the upper eyelid using Keratograph 5M and assessed ocular surface parameters including tear meniscus height and tear break-up time. MG density and vagueness values were automatically analyzed and calculated using an AI analytical system. We compared the differences between the affected and the contralateral unaffected eyes in HSK patients, and the normal control eyes. We employed either the paired *t*-test or the Wilcoxon signed-rank test to compare significant difference between the affected and unaffected eyes in HSK patients or between the HSK group and control group.

• **RESULTS:** The MG density was 0.19 ± 0.09 in the HSK-affected eye and 0.18 ± 0.07 in contralateral unaffected eye, which had no significant difference ($P=0.616$). The MG density between the affected eye with HSK and the normal control group was statistically significant ($P=0.028$). There was a significant difference in MG density between the contralateral unaffected eye and the normal control group ($P=0.012$). However, no significant difference in vagueness value was observed between the eye with HSK and the control group or between HSK eye and contralateral eye.

• **CONCLUSION:** The MG density between the HSK-

affected eye and the contralateral unaffected eye don't significantly differ, whereas there is a significant decrease in the HSK group compared to that of the normal participants. Unilateral HSV keratitis may suffer from bilateral changes of MG morphology indicating bilateral dry eye. Therefore, the fellow eye of patients with unilateral HSK should be considered a potential case of MG dysfunction, necessitating early treatment for bilateral dry eye in the clinic.

• **KEYWORDS:** herpes simplex keratitis; artificial intelligence; meibomian gland morphology; bilateral alterations

DOI:10.18240/ijo.2024.12.01

Citation: Yu XX, Chen XW, Dai Q, Wu SQ. Bilateral meibomian gland morphological alterations in unilateral herpes simplex keratitis based on artificial intelligence analysis. *Int J Ophthalmol* 2024;17(12):2153-2157

INTRODUCTION

The infection caused by herpes simplex virus (HSV) is a major contributor to corneal blindness^[1]. It primarily affects children and young adults through direct contact with mucus membranes or epithelial cells, often presenting as blepharitis, follicular conjunctivitis, and occasional punctate or dendritic keratitis^[2]. By the time reach to the age of 60y, approximately 90% of the population is seropositive for HSV infection^[3]. The virus enters the trigeminal ganglion *via* axoplasmic transport, where viral replication is inhibited, leading to latent infection. Reactivation of HSV commonly occurs during stress, fever, topical corticosteroids, or exposure to ultraviolet light^[4-5], most commonly presenting as herpes simplex keratitis (HSK).

Recurrent HSK can cause progressive corneal opacities, leading to impaired vision. The patient initially present with redness, foreign body sensation, pain, and impaired vision in the infected eyes. Clinical observations revealed that patients with HSK often had accompanying dry eye. This dryness may be caused by decreased corneal sensation, tear impairment, tear film instability, and neurotrophic dysfunction^[6-7]. Recent research has confirmed that unilateral HSV infection can also

affect the contralateral eye, leading to changes in the tear film, corneal nerve density, and endothelial cell density^[7-9]. Extensive research has indicated that patients suffering from unilateral herpetic interstitial keratitis may encounter dry eyes in the eye that remains unaffected on the other side^[10].

Dry eye syndrome represents a prevalent condition affecting the ocular surface, primarily caused by instability in the tear film, hyperosmolarity of tears, abnormalities on the ocular surface, inflammation, and neurosensory dysfunction accompanied by a series of ocular symptoms^[11]. Meibomian gland dysfunction (MGD) is one of the significant causes of dryness^[12]. Meibomian gland (MG) atrophy can lead to decreased MG function, which is closely related to MGD. Adil *et al*^[13] reported that the morphology of the MG had proven to be a valuable early sensitive indicator of MGD. Non-contact meibography techniques provide a direct means to visualize MGs *in vivo*. Previous studies on MG morphology have primarily concentrated on the meibograde, which is a semi-quantitative index used to assess MG loss. With the development of artificial intelligence (AI) technology, an increasing number of scholars are now focusing on MG length, tortuosity, and density.

AI analytic systems have been widely used to analyze MG images, reducing manual errors and saving time, which involving utilizing a convolutional neural network (CNN). Our previous study illustrated that the AI MG morphological analysis system could efficiently and accurately analyze the MG morphology^[14]. MG density is a sensitive parameter for the quantitative diagnosis of MG dropouts^[15]. MG vagueness value means MGs display intensity in meibography, which is mainly calculated by grayscale value of MGs minus grayscale value of background. Therefore, this study aimed to explore whether unilateral HSK could lead to significant morphological changes in the bilateral MGs taking advantage of an AI analysis system.

PARTICIPANTS AND METHODS

Ethical Approval This research was authorized by the Research Ethics Committee of the Eye Hospital of Wenzhou Medical University (approval number: 2021-258-K-224-02). The procedures complied with the principles of the Declaration of Helsinki. All participants granted informed consent for publication.

Participants In this retrospective study conducted from January 2019 to February 2021, we enrolled 29 individuals with unilateral HSK. The diagnosis of HSK relied primarily on patient history, typical clinical manifestations, or slit-lamp examination (evidencing characteristic epithelial defects or stromal lesions caused by HSV infection). In addition, many assistant examinations also used for diagnosing HSK, such as corneal confocal microscopy, and polymerase chain reaction.

The inclusion criteria comprised a history of unilateral HSK. We considered the affected eye and the unaffected contralateral eye as separate groups. The exclusion criteria included ocular trauma, surgery, or the use of soft contact lenses; systemic diseases, medications, or eye drops that affect MG function; and a history of bilateral HSK involvement or herpes zoster ophthalmicus (HZO). The control group consisted of 29 participants matched in terms of age and sex. To avoid statistical bias, only one eye from each participant was analyzed. None of the patients in the control group had HSK.

Ocular Surface Parameters and Meibomian Gland Morphology Analysis We acquired meibographic images of the upper eyelid using Keratograph 5M (K5M; Oculus, Wetzlar, Germany) and assessed ocular surface parameters such as tear meniscus height (TMH) and tear break-up time (TBUT). MG density and vagueness values were automatically analyzed and calculated using an AI analytical system, as introduced in our previously published article^[15]. Our AI system achieved 92% accuracy in MG segmentation with 100% repeatability.

Statistical Analysis Statistical analysis was conducted using IBM SPSS Statistics for Windows, version 26.0. We assessed the normality of all datasets using the Kolmogorov-Smirnov test. The data characteristics were expressed through descriptive statistics, including mean±standard deviation or median (interquartile range). We employed either the paired *t*-test or the Wilcoxon signed-rank test to compare significant difference between the affected and unaffected eyes in HSK patients or between the HSK group and control group. $P < 0.05$ were considered statistically significant.

RESULTS

The study comprised 29 HSK patients (14 males, 15 females) and 29 healthy participants (14 males, 15 females). Table 1 displays the essential demographic information of the patients. The average age was 61.93±13.93y for the HSK group and 61.82±14.02y for the control group. There was no statistically significant difference in TMH and TBUT between the HSK and control groups. Figure 1 exhibited the distinct meibographies of the normal control and HSK groups, and the segmented MG images by AI system highlighted in green.

To assess the influence of HSV infection on the morphology of MGs, we compared the MG morphological parameters, mainly MG density and vagueness, among patients with HSK (Table 2). The MG density of the upper eyelid was 0.19±0.09 in the HSK-affected eye and 0.18±0.07 in contralateral unaffected eye, which had no significant difference ($P=0.616$). The vagueness value was not statistically different between the HSK-affected eye (16.47±6.58) and the contralateral unaffected eye (17.96±6.56).

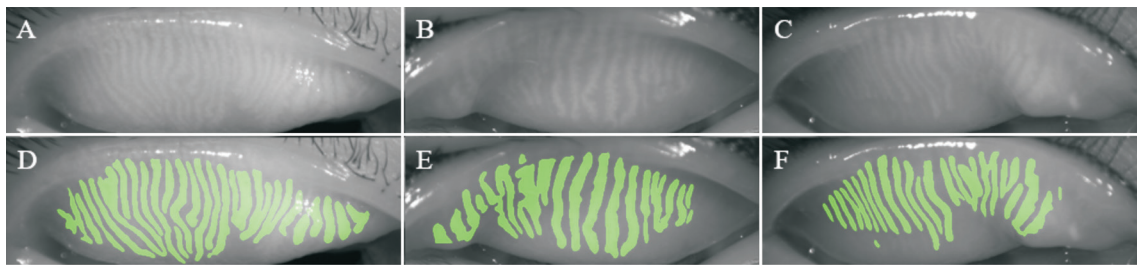


Figure 1 Samples of the original meibography, and AI segmentation of the MGs A: Meibography in the normal group; B: Meibography in contralateral unaffected eye; C: Meibography in the HSK eye; D-F: AI segmentation MGs of the upper eyelid. The segmented MG images by AI system highlighted in green, which indicated AI system having excellent recognition ability of MGs. AI: Artificial intelligence; MG: Meibomian gland; HSK: Herpes simplex keratitis.

Table 1 Basic characteristics and clinical parameters in the HSK group and control group

Characteristics	HSK group		Control group	P
	HSK eye	Contralateral unaffected eye		
Age (y), mean±SD	61.93±13.93		61.82±14.02	-
Gender (male/female)	14/15		14/15	-
TMH (mm), median (IQR)	0.23 (0.19, 0.30)	0.19 (0.16, 0.26)	0.22 (0.16, 0.27)	0.621
TBUT (s), median (IQR)	4.21 (2.82, 7.65)	4.62 (3.30, 7.79)	3.63 (2.55, 5.65)	0.610

SD: Standard deviation; IQR: Interquartile range; HSK: Herpes simplex keratitis; TBUT: Tear break-up time; TMH: Tear meniscus height.

Table 2 MG parameters in the HSK group and control group

Parameters	HSK group		Control group	P ¹	P ²	P ³
	HSK eye	Contralateral unaffected eye				
MG density	0.19±0.09	0.18±0.07	0.22±0.06	0.616	0.028 ^a	0.012 ^a
Vagueness value	16.47±6.58	17.96±6.56	18.96±6.44	0.244	0.121	0.493

¹HSK eye vs contralateral unaffected eye; ²HSK eye vs control group; ³Contralateral unaffected eye vs control group. MG: Meibomian gland; HSK: Herpes simplex keratitis. ^aP<0.05.

The MG density and vagueness values were also compared between the HSK and normal control groups (Table 2). The MG density between the affected eye with HSK and the normal control group was statistically significant (P=0.028). There was a significant difference in MG density between the contralateral unaffected eye and the normal control group (P=0.012). However, no significant difference in vagueness value was observed between the affected eye with HSK and the control group or between the unaffected contralateral eye and the control group (all P>0.05).

Additionally, the MG density and vagueness values did not correlate significantly with TBUT or TMH in the HSK group (P>0.05). In the control group, MG density exhibited a negative correlation with TBUT (r=-0.379, P<0.05; Table 3).

DISCUSSION

As is well known, dry eye is an important ocular surface disease, which often leads to excessive tear evaporation and reduced tear production. MG dropout as an indicator of MGD is related to the severity of MGD^[16]. Our previous study found that MG density was an alternative evaluation indicator for the meiboscore in the accurate and effective quantitative diagnosis of MG dropout^[15]. Inflammation is crucial in the development of dry eye. Many studies have confirmed that

Table 3 Correlations (r) of MG parameters with TBUT and TMH in the HSK group and control group

Parameters	TMH	TBUT
HSK eye		
MG density	0.084	-0.031
Vagueness value	0.077	-0.232
Contralateral unaffected eye		
MG density	0.135	0.165
Vagueness value	-0.108	0.110
Control group		
MG density	0.056	-0.379 ^a
Vagueness value	-0.039	-0.250

^aP<0.05. MG: Meibomian gland; HSK: Herpes simplex keratitis; TBUT: Tear break-up time; TMH: Tear meniscus height.

microbial keratitis can cause ocular surface inflammation, such as bacterial keratitis and HSK, which are associated with dry eye^[17]. Machalińska *et al*^[18] verified that rosacea, a chronic inflammatory disease, is accompanied by a significant loss of MG, manifested by reduced MG area and decreased MG density. Moreover, HSV infection can affect corneal sensation, tear film stability, and tear production, which are the main causes of dry eye. Many studies have reported that patients with herpetic interstitial keratitis experience dryness^[10]. In this

study, we aimed to understand the MG morphology in patients with HSK. No difference in MG density was observed between the affected eye with HSK and the unaffected contralateral eye. Our prior investigation on HZO demonstrated that the height and density of MGs were significantly lower in the affected eye with HZO compared to the unaffected contralateral eye. We speculate that the possible reason for this difference lies in the variations in viral replication and immune responses between HSK and HZO. Reactivation of varicella-zoster virus can spread throughout the entire ganglion and distribute to the dorsal root ganglion, while activation of HSV occurs within one neuron only^[19]. Compared to patients with HSK, those with HZO may experience more severe inflammatory reactions. In addition, we also calculated vagueness value, which no significant difference was observed between the HSK-affected eye and the contralateral unaffected eye or between the affected eye with HSK and the control group or between the unaffected contralateral eye and the control group. We speculated that the possible reason was that many patients had quiescent HSK, which conjunctival edema and ocular inflammation had disappeared. Therefore, the difference in vagueness values was not statistically significant.

Interestingly, we found that MG density was significantly reduced in HSK-affected eyes and contralateral unaffected eyes compared to the normal control group. Therefore, we believe that unilateral HSK may lead to bilateral impairment of MG morphology. We speculate the following as possible reasons for this phenomenon. First, HSV infection can trigger an inflammatory reaction, and unilateral HSK may lead to bilateral inflammation of the ocular surface, resulting in the impairment of MG morphology. Although the contralateral unaffected eye has no clinical history of HSK, it may harbor a potential subclinical infection with HSV^[20]. Thus, unilateral HSV infection may cause bilateral ocular inflammation associated with morphological changes in the MG. The chronic inflammatory disease is accompanied by a significant loss of MG, represented by a reduced MG area and decreased MG density. Second, a unilateral HSV infection may cause bilateral corneal nerve alterations which are related to corneal sensation. The reduction in corneal sensation and corneal nerves may result in a decreased blink rate, increased tear osmolarity, and instability of the tear film, which may also alter the morphology of MGs. Hamrah *et al*^[7] and Müller *et al*^[21] demonstrated that the contralateral unaffected eyes had a dramatic decrease in the subbasal nerve plexus after infection with HSV. Therefore, unilateral infections lead to bilateral nerve alterations that may be regulated by the central nervous system in a neurogenic manner^[7,22-23]. Third, unilateral HSK may cause bilateral tear impairment, leading to increased tear osmolarity and tear film abnormalities, which in turn, causes

morphological changes in the MGs. Tear hyperosmolarity is mainly attributed to a reduction in tear secretion, occurring in the early stages of dry eye, and is closely related to its severity^[24]. Elevated tear osmolarity can also cause ocular surface inflammation and alter the function of the tear film^[10]. Ma and Lu^[25] and Simard-Lebrun *et al*^[10] demonstrated that compared with controls, unilateral HSK caused a decrease in bilateral basal and reflex tears. Hypertonic tears can also alter the structure of the corneal nerves, significantly reducing corneal sensitivity^[24]. However, corneal sensitivity can also lead to abnormal tear secretion, creating a vicious cycle.

Previous studies on MG morphology primarily focused on meibograde, which is a semi-quantitative index used to assess MG loss, but it is unstable and inaccurate. MG density represents a quantitative parameter defined as the ratio of the cumulative MGs area to the entire tarsus area. Manual labeling, owing to the inability to control variables, is time-consuming and prone to errors, limiting the clinical application of MG density. An AI analytic system can eliminate errors in manual analysis and save time in image processing. Therefore, we investigated the change of MG density based on the AI morphological analysis system in our study. To date, this is the first study to explore MG morphology in patients with HSK based on an AI analysis system.

In summary, unilateral HSK could cause morphological changes in bilateral MGs, resulting in a decrease in MG density. We speculate that the possible causes are ocular surface inflammation, corneal sensation, corneal nerve alteration, tear osmolarity, and tear film abnormalities. However, it is important to note that this study has certain limitations. It was a retrospective investigation with a relatively small sample size. Considering the complex causes of MGD, a prospective study with a larger sample size is needed to verify the cause of morphological changes in the bilateral MGs in patients with HSK. In addition, more detailed classification of the type and stage of HSK should be concerned. Our study was a retrospective study and details on the duration and severity of HSK were difficult to obtain accurately. Subsequent studies will consider more details on the duration and severity of HSK. Moreover, our study did not address the effect of different times of the affected eye with HSK on MG morphology. Therefore, extend the follow-up time of the affected eye with HSK and compare the morphological changes of MGs at different time points after the onset of HSK could make our study more reliable.

In conclusion, our study found that the MG density was a significant decrease in the HSK group compared to that of the normal participants. There was no significant difference of the MG density and vagueness value between the HSK-affected eye and the contralateral eye. We also found no correlation

between the MG density and TBUT or TMH in the HSK group. Further research may be needed to explore possible causes. Considering MG density as a well-known sensitive diagnostic indicator for MGD, we proposed that unilateral HSK may induce bilateral changes in MG morphology and bilateral dry eye, associated with inflammation and corneal nerve alteration. Therefore, the fellow eye of patients with unilateral HSK should be concerned, necessitating early treatment for bilateral dry eye in the clinic.

ACKNOWLEDGEMENTS

Foundations: Supported by Zhejiang Provincial Medical and Health Science Technology Program, Health Commission of Zhejiang Province (No.2022PY074); Science and Technology Program of Wenzhou City (No.Y2020335).

Conflicts of Interest: Yu XX, None; Chen XW, None; Dai Q, None; Wu SQ, None.

REFERENCES

- 1 Lin TL, Cheng C, Zeng WT, Duan F, Pei YH, Liu XP, Shang F, Wu KL. Anti-viral activity of *Staphylococcus aureus* lysates against herpes simplex virus type-I infection: an *in vitro* and *in vivo* study. *Int J Ophthalmol* 2021;14(10):1463-1472.
- 2 Lobo AM, Agelidis AM, Shukla D. Pathogenesis of herpes simplex keratitis: the host cell response and ocular surface sequelae to infection and inflammation. *Ocul Surf* 2019;17(1):40-49.
- 3 Labib BA, Chigbu DI. Clinical management of herpes simplex virus keratitis. *Diagnostics* 2022;12(10):2368.
- 4 Arshad S, Petsoglou C, Lee T, Al-Tamimi A, Carnt NA. 20 years since the Herpetic Eye Disease Study: lessons, developments and applications to clinical practice. *Clin Exp Optom* 2021;104(3):396-405.
- 5 Yin XT, Baugnon NK, Krishnan R, Potter CA, Yarlagadda S, Keadle TL, Stuart PM. CD137 costimulation is associated with reduced herpetic stromal keratitis and with developing normal CD8⁺ T cells in trigeminal ganglia. *J Gen Virol* 2022;103(6):001756.
- 6 Mittal R, Patel S, Galor A. Alternative therapies for dry eye disease. *Curr Opin Ophthalmol* 2021;32(4):348-361.
- 7 Hamrah P, Cruzat A, Dastjerdi MH, Zheng LX, Shahatit BM, Bayhan HA, Dana R, Pavan-Langston D. Corneal sensation and subbasal nerve alterations in patients with herpes simplex keratitis: an *in vivo* confocal microscopy study. *Ophthalmology* 2010;117(10):1930-1936.
- 8 Keijser S, van Best JA, van der Lelij A, Jager MJ. Reflex and steady state tears in patients with latent stromal herpetic keratitis. *Invest Ophthalmol Vis Sci* 2002;43(1):87-91.
- 9 M'Garrech M, Rousseau A, Kaswin G, Sauer A, Barreau E, Bourcier T, Labetoulle M. Impairment of lacrimal secretion in the unaffected fellow eye of patients with recurrent unilateral herpetic keratitis. *Ophthalmology* 2013;120(10):1959-1967.
- 10 Simard-Lebrun A, Boisjoly H, Al-Saadi A, Choremis J, Mabon M, Chagnon M. Association between unilateral quiescent stromal herpetic keratitis and bilateral dry eyes. *Cornea* 2010;29(11):1291-1295.
- 11 Rao SK, Mohan, Gokhale N, Matalia H, Mehta P. Inflammation and dry eye disease-where are we? *Int J Ophthalmol* 2022;15(5):820-827.
- 12 Jo YJ, Lee JE, Lee JS. Clinical efficacy of 0.05% cyclosporine nano-emulsion in the treatment of dry eye syndrome associated with meibomian gland dysfunction. *Int J Ophthalmol* 2022;15(12):1924-1931.
- 13 Adil MY, Xiao JX, Olafsson J, Chen XJ, Lagali NS, Ræder S, Utheim ØA, Dartt DA, Utheim TP. Meibomian gland morphology is a sensitive early indicator of meibomian gland dysfunction. *Am J Ophthalmol* 2019;200:16-25.
- 14 Dai Q, Liu XY, Lin XL, Fu YN, Chen CQ, Yu XX, Zhang ZH, Li TK, Liu MT, Yang WH, Ye J. A novel meibomian gland morphology analytic system based on a convolutional neural network. *IEEE Access* 2021;9:23083-23094.
- 15 Zhang ZH, Lin XL, Yu XX, Fu YN, Chen XY, Yang WH, Dai Q. Meibomian gland density: an effective evaluation index of meibomian gland dysfunction based on deep learning and transfer learning. *J Clin Med* 2022;11(9):2396.
- 16 Giannaccare G, Vigo L, Pellegrini M, Sebastiani S, Carones F. Ocular surface workup with automated noninvasive measurements for the diagnosis of meibomian gland dysfunction. *Cornea* 2018;37(6):740-745.
- 17 Narayanan S, Redfern RL, Miller WL, Nichols KK, McDermott AM. Dry eye disease and microbial keratitis: is there a connection? 2013;11(2):75-92.
- 18 Machalińska A, Zakrzewska A, Markowska A, Safranow K, Wiszniewska B, Parafiniuk M, Machaliński B. Morphological and functional evaluation of meibomian gland dysfunction in rosacea patients. *Curr Eye Res* 2016;41(8):1029-1034.
- 19 Yu XX, Jia X, Zhang ZH, Fu YN, Zhai J, Chen NM, Cao QX, Zhu ZT, Dai Q. Meibomian gland morphological changes in ocular herpes zoster patients based on AI analysis. *Front Cell Dev Biol* 2022;10:1094044.
- 20 Kumar M, Hill JM, Clement C, Varnell ED, Thompson HW, Kaufman HE. A double-blind placebo-controlled study to evaluate valacyclovir alone and with aspirin for asymptomatic HSV-1 DNA shedding in human tears and saliva. *Invest Ophthalmol Vis Sci* 2009;50(12):5601-5608.
- 21 Müller RT, Pourmirzaie R, Pavan-Langston D, Cavalcanti BM, Aggarwal S, Colón C, Jamali A, Cruzat A, Hamrah P. *In vivo* confocal microscopy demonstrates bilateral loss of endothelial cells in unilateral herpes simplex keratitis. *Invest Ophthalmol Vis Sci* 2015;56(8):4899-4906.
- 22 Liu XT, Xu S, Wang YB, Jin X, Shi Y, Zhang H. Bilateral limbal stem cell alterations in patients with unilateral herpes simplex keratitis and herpes zoster ophthalmicus as shown by *in vivo* confocal microscopy. *Invest Ophthalmol Vis Sci* 2021;62(6):12.
- 23 Pfaller K, Arvidsson J. Central distribution of trigeminal and upper cervical primary afferents in the rat studied by anterograde transport of horseradish peroxidase conjugated to wheat germ agglutinin. *J Comp Neurol* 1988;268(1):91-108.
- 24 Hirata H, Mizerska K, Marfurt CF, Rosenblatt MI. Hyperosmolar tears induce functional and structural alterations of corneal nerves: electrophysiological and anatomical evidence toward neurotoxicity. *Invest Ophthalmol Vis Sci* 2015;56(13):8125-8140.
- 25 Ma X, Lu Y. Bilateral tear film alterations in patients with unilateral quiescent herpes simplex keratitis. *Acta Ophthalmol* 2017;95(6):629-633.